

Orbital mucormycosis in an immunocompetent individual

Badiee P¹, Jafarpour Z^{1*}, Alborzi A¹, Haddadi P², Rasuli M¹, Kalani M¹

¹Prof. Alborzi Clinical Microbiology Research Center, ²Student Research Committee, Shiraz University of Medical Sciences, Shiraz, Iran.

Received: June 2012, Accepted: August 2012.

ABSTRACT

Background: Orbital mucormycosis caused by Zygomycetes is a rare and fatal infection that generally affects the patients who are immunocompromised. Despite antifungal therapy and aggressive surgical intervention, mucormycosis can cause serious and rapidly fatal infections if delayed diagnosis or therapeutic management occurs. Here, we report orbital mucormycosis in a healthy boy, with a favorable outcome after aggressive treatment. He has had no recurrence since the end of his treatment.

Case present: A 2-year old healthy boy, some days after entry of dust particle to his left eye presented with swelling and redness of the eye. With diagnosis of "periorbital cellulitis" intravenous antibiotics vancomycin (40 mg/kg/day) and ceftriaxone (75 mg/kg/day) were started but no improvement was observed. The results of biopsy and tissue culture led us to a diagnosis of mucormycosis. Orbital exenteration, combined with intravenous amphotericin B (1 mg/kg/day), resulted in the patient's survival.

Conclusion: Due to the high mortality rate of mucormycosis, early diagnosis based on clinical findings and biopsy could be effective for management of the patients suffering from this infection.

Keyword: mucormycosis, immunocompetent, orbital exenteration, amphotericin B

INTRODUCTION

Mucormycosis is a life threatening and opportunistic fungal infection caused by fungi of the *Mucorales* order belonging to the *Phycomycetes* class of which, the main pathogens belong to the *Rhizomucor*, *Rhizopus*, *Absidia* and *Mucor* species (1, 2). This infection is uncommon but the incidence appears to be increasing (1, 3, 4). Dounia Bitar et al. documented an increasing incidence of zygomycosis from 0.7/million in 1997 to 1.2/million in 2006

($p < 0.001$) (5). Despite antifungal therapy and aggressive surgical intervention, mucormycosis can cause serious and rapidly fatal infections if delayed diagnosis or therapeutic management occurs. Here, we report orbital mucormycosis in a healthy boy, with a favorable outcome after aggressive treatment.

CASE REPORT

A 2-year old boy was referred to Nemazee hospital, Shiraz University of Medical Sciences, Shiraz, Iran in the spring 2010 with 18 days history of swelling and redness of left eye. He had history of the entry of some dust particle into his left eye, after that a redness of left eye developed that aggravated during a week. He had been admitted to another hospital and periorbital cellulitis was diagnosed and the patient received vancomycin (40 mg/kg/day) and ceftriaxone (75 mg/kg/day) for 10 days, but no improvement

* Corresponding author: Zahra Jafarpour MD
Adress: Prof. Alborzi Clinical Microbiology Research Center, Post Code 7193711351, Nemazee Hospital, Zand Ave., Shiraz, Iran.
Tel.: +98-711-6474304
Fax: +98-711-6474303
E-mail: zjafarpour54@yahoo.com

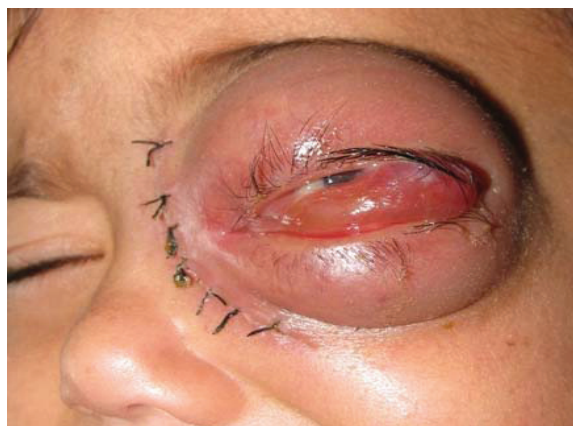

Fig. 1. Swelling of upper and lower lid in the patient with mucormycosis.

was observed and referred to Nemazee hospital. At examination, swelling of upper and lower lids, more prominent on lower part was seen (Fig. 1). Proptosis, conjunctival congestion and chemosis and limitation of motion in all directions were seen. Clindamycin (40 mg/kg/day) and ceftriaxone (75 mg/kg/day), was initiated. For measurement of visual acuity and gonioscopy, he was not cooperative. Pupil shape, reactivity, and size and lacrimal drainage system were normal, and nystagmus was negative. His past medical history was significant only for chronic itching of eyes prior first admission.

Laboratory investigation revealed: white cell count $18.2 \times 10^3/\text{mm}^3$, neutrophil:3 2%, lymphocyte 50%, monocyte 14%, eosinophil 4%, hemoglobin 10.4 g/dL, mean corpuscular volume (MCV) 67.1 fl, mean corpuscular hemoglobin (MCH) 18.6 pg, platelet count $152000/\text{mm}^3$, ESR 25 mm/1sthour, C. reactive protein 6, blood sugar 85 mg/dl. Total cerebrospinal fluid (CSF) cell count was 10 including 2 white blood cell (all lymphocyte). The sugar and protein of CSF were 69 and 22 mg/dl, respectively. Gram staining of CSF did not show any organism. Other rare disorders that present with proptosis such as Wegener granulomatosis, leukemia, Burkitt lymphoma and histiocytosis were investigated. Peripheral antineutrophil cytoplasmic antibodies (P-ANCA) and C-Anti-neutrophil cytoplasmic antibodies (C-ANCA) were negative and bone marrow aspiration and trephine biopsy revealed normocellular marrow with no evidence of metastasis. Immunohistochemical study for S_{100} , CD_{30} , CD_{20} , CD_3 and BCL-2, myeloperoxidase was negative in histocyte-like cells.

Computer tomography scan of the orbits

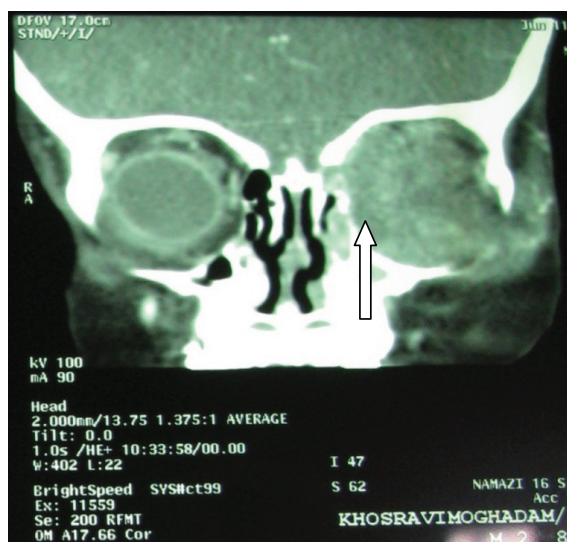


Fig. 2. Computer tomography scan of the orbits of patient with mucormycosis. It demonstrated partly cystic solid occupying lesion with central necrosis in the medial aspect of left orbit with irregularity of the wall.

demonstrated partly cystic solid occupying lesion in the medial aspect of left orbit with compression of the optic nerve and irregularity of the wall with central necrosis detected (Fig. 2).

Anterior orbitotomy and orbital mass biopsy of the left eye were done, no evidence of pus was detected and only necrotic tissue was seen. Four pieces of creamy-white, rubbery tissue was removed and sent to pathology and mycology labs. The pathology result was reported as vague aggregates of histiocytes with perivascular lymphocyte. Some areas of necrosis with hyphen elements were detected. In the mycology lab, direct smear of tissue with potassium hydroxide showed non-septated hyphae (Fig. 3) and after culture the sample on Sabouraud Dextrose Agar (Merck, Darmstadt, Germany); diagnosis was documented with growth of *Mucor* in culture (Fig. 4, 5). Immunological studies revealed normal levels of IgG_1 , IgG_2 , IgG_3 , IgG_4 , IgA , C_3 , C_4 , CD_3^+ (T-cell), CD_4^+ (helper T-cell), CD_8^+ (cytotoxic T-cell), CD_{16} , CD_4^+/CD_8^+ ratio, B-cell, and Natural killer cell. HIV test, blood and sinus culture results were negative.

Surgical exenteration of the left eye was done and amphotericin B (1 mg/kg) and clindamycin (30 mg/kg) daily were started for him. He was discharged after about 4 weeks and treatment was extended with itraconazole (5 mg/kg/day) for 6 months. Two-year follow up examination revealed no evidence of recurrence.

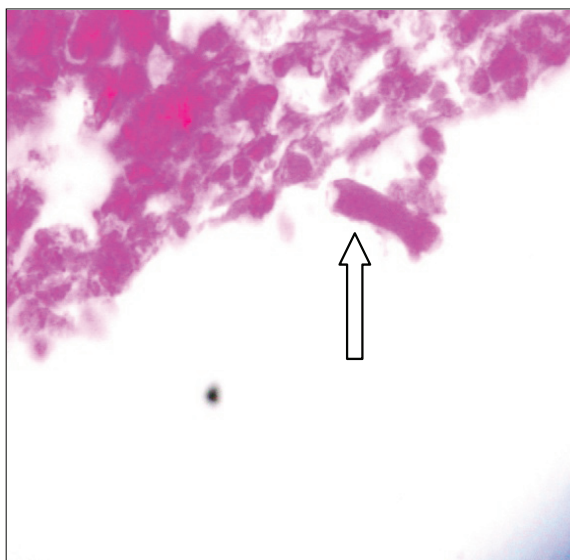


Fig. 3. Orbital tissue showing typical non septate hyphae.

Ethical consideration. The ethics committee of Clinical Microbiology Research Center, Shiraz University of Medical Sciences has reviewed and approved the study regarding the patient written consents before participating in the study.

DISCUSSION

Mucormycosis caused by Zygomycetes is a rare and fatal infection that generally affects the patients who are immunocompromised. It generally affects almost

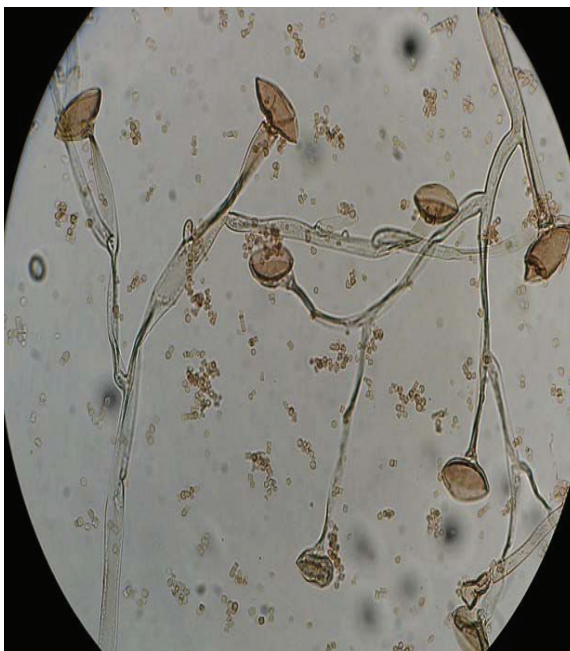

Fig. 5. *Mucor* species-microscopic morphology, 400x Lactophenol cotton blue.

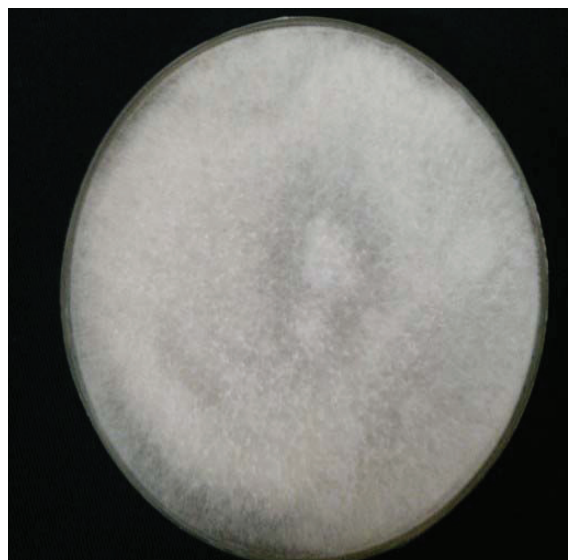


Fig. 4. *Mucor* spp. isolated from tissue culture.

exclusively the patients with known predisposing conditions, such as poorly controlled diabetes, long term consumption of steroid, antibiotics, and cytotoxic agents, leukemia, lymphoma, organ transplantation, severe burns, hemochromatosis and use of deferoxamine and possibly malnutrition considering the majority of cases occurring in the developing nations (6, 7). Furthermore, previous use of antifungal drugs lacking activity against *Zygomycetes* has coincided with an increase in the incidence of *Mucorals* (5, 8). In the present study, the evaluation of immunological factors revealed that the patient was healthy with non-risk factor for mucormycosis. We also found in the literature some cases of primary fungal infections (9) and mucormycosis in the patients with no underlying disease; in the breast (10), maxillary first molar (11) gastrointestinal (12), and in rhino-orbital-cerebral mucormycosis after a high pressure water jet injury (13). The interior of the eye does not contain lymphoid vessels but is highly vascularized, so that in healthy persons ocular immune system is sufficient to prevent infection except cases of massive contamination with traumatic inoculation (8, 14). The patient in the present study had only the history of the entry of dust particle into his eye and itching led it to deeper layers of the eye.

Although there have been reports of mucormycosis, true orbital infection in healthy individuals is very rare (13-16).

Although molecular and serological methods for the diagnosis of some etiologic agents causing invasive fungal infections have been reported (17-19), the gold

standard for the diagnosis of mucormycosis like other fungal diseases is tissue culture and in this study, the causative agent was isolated from the culture media. Unfortunately, no serological method is available for the diagnosis of mucormycosis, and there are very few reports on the molecular method for the diagnosis of this infection (20).

Chamilos G et al. showed that early diagnosis of mucormycosis and initiation of appropriate therapy within 5 days contributed to the improvement in the respective patient's survival, compared with the initiation of therapy at ≥ 6 days (83% vs. 49% survival) (21). Standard treatment in immunocompromised patients requires discontinuation of immunosuppressive drugs like cyclosporine or mycophenolatemofetil, along with aggressive surgical debridement and systemic antifungal therapy. Despite advances in diagnosis and aggressive surgical and polyene antifungal therapy, a high mortality rate of 30-70% still exists for the disease (22). The modalities of treatment are rapid diagnosis, surgical intervention, and antifungal agents (23, 24). Due to some areas of necrosis and poor penetration of amphotericin B into the blood brain barrier, surgical debridement was necessary (25). Lipid formulations of amphotericin B (LFABs) are less nephrotoxic and can be used as antifungal agent at higher doses and a longer time than amphotericin B (26, 27). In this study, as the patient had the normal immunological condition, after exenteration of left eye, amphotericin B (1 mg/kg) was started in the hospital and then itraconazole was extended for 6 months. There is a report on a successful therapy for a healthy patient, treated with debridement and fluconazole (11). Due to the high mortality rate of mucormycosis, early diagnosis based on clinical findings and biopsy could be very effective for management of the patients suffering from this infection.

ACKNOWLEDGEMENT

Our thanks are due to Hassan Khajehei, PhD for his careful copy editing of the manuscript.

REFERENCES

- Santos Gorjón P, Blanco Pérez P, BatuecasCaletrío A, Muñoz Herrera AM, Sánchez González F, de la FuenteCañibano R. Rhino-orbito-cerebral mucormycosis, a retrospective study of 7 cases. *Acta Otorrinolaringol Esp* 2010; 61: 48-53.
- Paulltauf A. Mycosis mucorina. *Virchows Arch* 1885; 102: 543-64.
- Gleissner B, Schilling A, Anagnostopolous I, Siehl I, Thiel E. Improved outcome of zygomycosis in patients with hematological diseases? *Leuk Lymphoma* 2004; 45: 1351-1360.
- Roden MM, Zaoutis TE, Buchanan WL, Knudsen TA, Sarkisova TA, Schaufele RL, et al. Epidemiology and outcome of zygomycosis: a review of 929 reported cases. *Clin Infect Dis* 2005; 41: 634-653.
- Bitar D, Van Cauteren D, Lantermier F, Dannaoui E, Che D, Dromer F, et al. Increasing incidence of zygomycosis (Mucormycosis), France, 1997-2006. *Emerg Infect Dis* 2009; 15: 1395-401.
- Albert DM, Lesser RL, Cykiert RC, Zakov ZN. Orbitofacial mucormycosis with unusual pathological features. *Br J Ophthalmol* 1979; 63: 699-703. British Journal of Ophthalmologybj.ojpubs.bmj.com
- Elinav H, Zimhony O, Cohen MJ, Marcovich AL, Benenson S. Rhinocerebral mucormycosis in patients without predisposing medical conditions: a review of the literature. *Clin Microbiol Infect* 2009; 15: 693-697.
- Castón-Osorio JJ, Rivero A, Torre-Cisneros J. Epidemiology of invasive fungal infection. *Int J Antimicrob Agents* 2008; 32: 103-109.
- Badiee P, Alborzi A, Farhoudi A. A case of *Candida* mediastinitis after dental extraction. *J Infect Dev Ctries* 2011; 5: 75-78.
- Baezzat SR, Fazelzadeh A, Tahmasebi S, Kumar PV. Primary Breast Mucormycosis, a case report. *Iran Red Crescent Med J* 2011; 13: 208-209.
- Yazdani J, Nezafati S, Arta SA, Ghavimi MA, Ghoreishizadeh A. Mucormycosis infection in a healthy patient. *Medical Journal of Tabriz University* 2011; 33 (4).
- Shiva Prasad BN, Shenoy A, Nataraj KS. Primary gastrointestinal mucormycosis in an immunocompetent person. *J Postgrad Med* 2008; 54: 211-213.
- Fairley C, Sullivan TJ, Bartley P, Allworth T, Lewandowski R. Survival after rhino-orbital-cerebral mucormycosis in an immunocompetent patient. *Ophthalmology* 2000; 107: 555-558.
- O'Keefe M, Haining WM, Young JD, Guthrie W. Orbital mucormycosis with survival. *Br J Ophthalmol* 1986; 70: 634-636.
- Martín-Moro JG, Calleja JM, García MB, Carretero JL, Rodríguez JG. Rhino orbito cerebral mucormycosis: a case report and literature review. *Med Oral Patol* 2008; 13: 792-795.
- Gass JDM. Acute orbital mucormycosis. Report of two cases. *Arch Ophthalmol* 1961; 65: 214-220.
- Badiee P, Alborzi A, Karimi M, Pourabbas B, Haddadi P, Mardaneh J, et al. Diagnostic potential of nested PCR, galactomannan EIA, and beta-D-glucan for invasive aspergillosis in pediatric patients. *J Infect Dev Ctries* 2012; 6:352-327.
- Badiee P, Alborzi A, Joukar M. Molecular assay to detect nosocomial fungal infections in intensive care units. *Euro J Intern Med* 2011; 22: 611-615.
- Badiee P, Alborzi A. Assessment of a Real-time PCR

- method to detect human non-cryptococcal fungal meningitis. *Arch Iran Med* 2011; 14: 381-384.
20. Rickerts V, Just-Nubling G, Konrad F, Kern J, Lambrecht E, Bohme A, et al. Diagnosis of invasive aspergillosis and mucormycosis in immunocompromised patients by semi-nested PCR assay of tissue samples. *Eur J Clin Microbiol Infect Dis* 2006; 25: 8-13.
 21. Chamilos G, Lewis RE, Kontoyiannis DP. Delaying amphotericinB-based frontline therapy significantly increases mortality among patients with hematologic malignancy who have zygomycosis. *Clin Infect Dis* 2008; 47: 503-509.
 22. Damante JH, Fleury RN. Oral and rhino-orbital mucormycosis. *J Oral Maxillofac Surg* 1998; 56: 267-271.
 23. Peterson KL, Wang M, Canalis RF, Abemayor E. Rhinocerebral mucormycosis: evolution of the disease and treatment options. *Laryngoscope* 1997; 107: 855-862.
 24. Spellberg B, Walsh TJ, Kontoyiannis DP, Edwards J, Ibrahim AS: Recent advances in the management of mucormycosis: from bench to bedside. *Clin Infect Dis* 2009; 48: 1743-1751.
 25. Yoon YK, Kim MJ, Chung YG, Shin IY. Successful treatment of a case with rhino-orbital-cerebral mucormycosis by the combination of neurosurgical intervention and the sequential use of amphotericin B and posaconazole. *J Korean Neurosurg Soc* 2010; 47: 74-77.
 26. Reed C, Bryant R, Ibrahim AS, Edwards J, Filler SG, Goldberg R et al. Combination polyene-caspofungin treatment of rhino-orbital-cerebral mucormycosis. *Clin Infect Dis* 2008; 47: 364-371.
 27. Walsh TJ, Finberg RW, Arndt C, et al. Liposomal amphotericin B for empirical therapy in patients with persistent fever and neutropenia. National institute of allergy and infectious diseases mycoses study group. *N Engl J Med* 1999; 340: 764-771.