

## A case of onychomycosis caused by a terbinafine-susceptible *Fusarium solani* in Vietnam

Thi Minh Chau Ngo\*, Phuong Anh Ton Nu, Le Chi Cao, Thi Ngoc Thuy Ha, Thi Bich Thao Do, Giang Tran Thi

Department of Parasitology, Hue University of Medicine and Pharmacy, Hue University, Hue, Viet Nam

Received: August 2022, Accepted: November 2022

### ABSTRACT

*Fusarium* spp. are the common onychomycosis pathogens in non-dermatophyte molds, and are considered resistant to many antifungal agents. We reported onychomycosis of the fingernail caused by *Fusarium solani* in Vietnam. The minimum inhibitory concentration of terbinafine against the tested isolate was 1 µg/ml, which was the lowest of all antimycotic agents. The patient was successfully treated with a daily dose of 250mg terbinafine for two months, and no recurrence occurred after a one-year follow-up. Antifungal susceptibility testing is recommended in *Fusarium* onychomycosis.

**Keywords:** Onychomycosis; *Fusarium solani*; Terbinafine susceptible; Antifungal susceptibility testing; Onychomycosis treatment

### INTRODUCTION

Onychomycosis is a disease caused by fungal pathogens that leads to nail discoloration, thickness, and separation from the nail bed. Dermatophytes, yeasts, and non-dermatophyte molds (NDMs) are the causative agents of the disease, although NDMs are less responsible for this disease than dermatophytes (1, 2). The *Aspergillus* spp., *Scopulariopsis brevicaulis*, *Fusarium* spp., *Acremonium* spp., *Scybalidium dimidiatum*, and *Scybalidium hyalinum* are the most commonly isolated NDMs associated with onychomycosis (1, 3-7). *Fusarium* is a saprophytic fungus found in the environment. The species complexes encountered in onychomycosis are *Fusarium solani*, *Fusarium oxysporum*, *Fusarium fujikuroi*, and *Fusarium dimerum*, of which *Fusarium solani* complex

is the most common etiologic species (2). Predisposing factors for *Fusarium* onychomycosis may include age, gender, nail traumatic injury, diabetes, hypertension, HIV, and autoimmune disease (2). However, this fungus can cause the primary infection without risk factors (2, 8). Infection often affects the big toenails with the common clinical subtype of distal-lateral subungual onychomycosis (DLSO) (2).

*Fusarium* onychomycosis is difficult to cure with antifungal agents and has a high failure rates even after a prolonged course of systemic antifungal or topical therapy. As NDMs onychomycosis has been increasingly reported (1, 2), the clinical subtype and use of antifungal agents in *Fusarium* infections have gained the attention of mycologists and dermatologists worldwide (2, 9, 10). This case report focuses on antifungal susceptibility testing and patient fol-

\*Corresponding author: Thi Minh Chau Ngo, MD, Ph.D, Department of Parasitology, Hue University of Medicine and Pharmacy, Hue University, Hue, Viet Nam. Tel: +84983863426 Email: ntmchau@hueuni.edu.vn

low-up after treatment to contribute to the choice of treatment for *Fusarium* nail infection.

**CASE PRESENTATION**

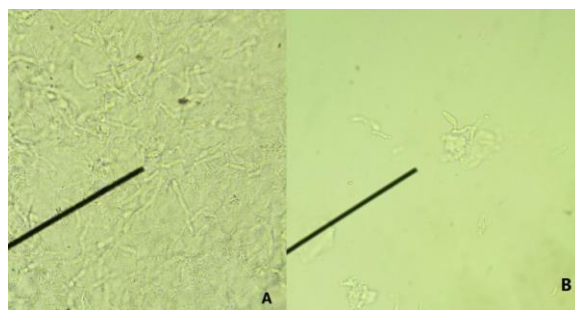
A 35-year-old nurse visited the Department of Clinical Dermatology at the Hue University of Medicine and Pharmacy Hospital in July 2021. She had a lesion on her right ring finger with a whitish discoloration at a distal-lateral nail corner, then the infection invaded the nail bed and gradually spread across the width of the nail plate, resulting in onycholysis. The nail damage occurred seven months before the clinical examination, with no history of trauma or related diseases and no contact with animals. She had taken the contraceptive pills five years ago.

The clinical dermatologic examination revealed DLSO (Fig. 1A). Nail scrapings were collected and examined with a potassium hydroxide preparation. Microscopic examination revealed an abundance of septate hyaline hyphae (Fig. 2A), and some elements resembling fungal conidia (Fig. 2B). Nail samples were initially cultured on Sabouraud Dextrose Agar medium supplemented with chloramphenicol at 28°C. Colonies grew rapidly within five days and formed a rich, cream-colored mycelium. Subsequently, the fungi were subcultured into Potato Dextrose Agar (PDA) medium. After three days, the fungal colony exhibited dense, smooth, white mycelium (Fig. 3A); and the reverse color was reddish in the center and yellow in peripheral areas (Fig. 3B). Microscopically, the septate hyaline hyphae were 4-5 microns in diameter and branched at acute angles with numerous microconidia and sparse macroconidia. The micro-

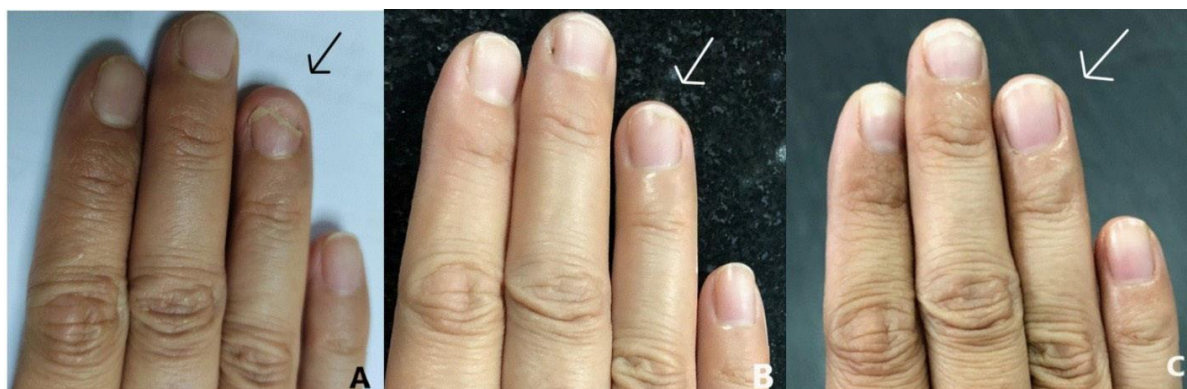conidia were hyaline, unicellular to bicellular, cylindrical to oval, and formed long lateral phialides. The macroconidia were fusiform, cylindrical, moderately curved, and three-four septate (Fig. 3C). Based on the morphology, the primary fungal identification was the *F. solani* species complex.

Deoxyribonucleic acid (DNA) of fungi was extracted, and polymerase chain reaction (PCR) was performed to amplify the internal transcribed sequences (ITS) rDNA region, as our previously published (11). *Trichophyton rubrum* ATCC 28188 was used as a positive control. The presence of a specific band of around 550 bp was considered a DNA detection target (Fig. 4).

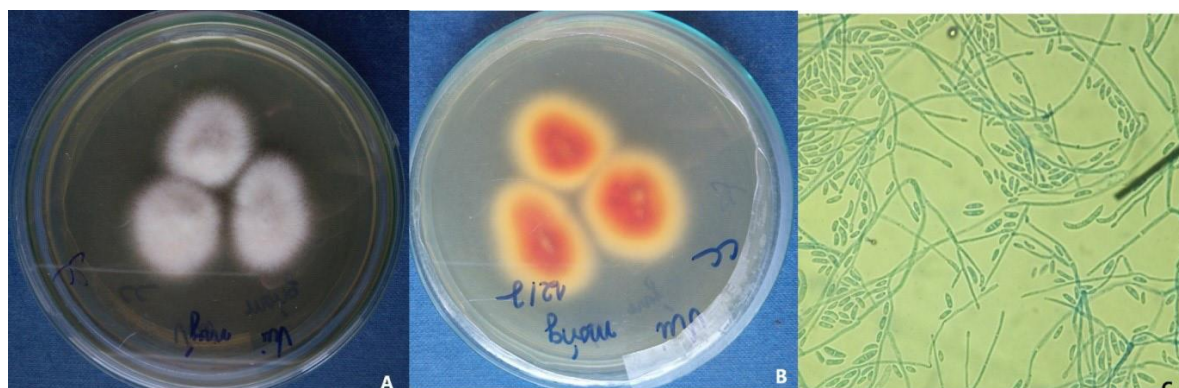The amplicons were sent for purification and sequencing at the 1st Base DNA Sequencing Service, Malaysia. The new sequence was analyzed using BLAST in GenBank. Then, this sequence was aligned with Bioedit 7.2.5 to check the similarity with reference isolates, including MH865999 *Fusarium solani* and NR\_130690 *Fusarium keratoplacticum*. The result showed that this isolate was *Fusarium solani*.



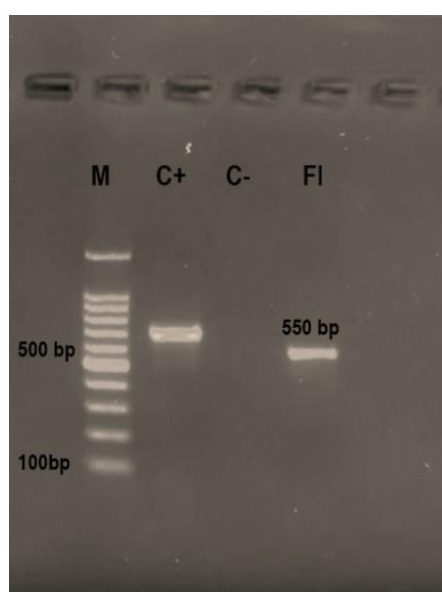
**Fig. 2.** Microscopic characteristics of nail scrapes: (A). Septate hyaline hyphae; (B). Hyphae with a part element like conidia.



**Fig. 1.** Patient fingernail (with the arrow): (A). At the beginning of treatment; (B). After two months of treatment; (C). One-year follow-up after treatment.



**Fig. 3.** Fungal cultivation characteristics: (A), (B). Macroscopic morphology on PDA, (C). Microscopic morphology in Lactophenol cotton blue staining at 400× magnification.



**Fig. 4.** Electrophoretic patterns PCR: M. 100 bp marker; C(+). Positive control; C(-). Negative control; FI. fungal isolate.

Our ITS sequence has been deposited in the Genbank database under accession number OP164798.

The minimum inhibitory concentrations (MIC) values of antifungal agents, including itraconazole (Sigma-Aldrich), voriconazole (AK Scientific, Inc, USA), amphotericin B (Sigma -Aldrich), caspofungin (Sigma-Aldrich), and terbinafine (Sigma -Aldrich) were determined to this isolate using the broth microdilution assay mainly according to the protocol of EUCAST (E.Def. 9.4) for molds (12). *A. fumigatus* ATCC 204305 was used as a quality control strain.

The result showed that the MIC values of this isolate were >8 µg/ml for itraconazole, 8 µg/ml for

voriconazole, >8 µg/ml for amphotericin B, >8 µg/ml for caspofungin, and 1 µg/ml for terbinafine. The patient was treated with oral terbinafine at a dose of 250mg per day for two months. The patient's follow-up showed that the damage to her fingernail gradually regressed, with significant recovery after 2 months (Fig. 1B). At 1-year follow-up, there was no relapse (Fig. 1C).

## DISCUSSION

Non-dermatophyte molds are thought to be responsible for 10% of all onychomycosis cases (1). *Fusarium* species have been considered the common causative agent of onychomycosis caused by NDMs (3-6). According to a review by Uemura et al. there is a difference in the geographic distribution of these fungal species isolates in *Fusarium* onychomycosis, with the *F. solani* complex being the most common fungal group in Asia and Africa, while the *F. oxysporum* complex was most abundant in Europe (2).

*F. solani* identified by molecular technique in this case report is consistent with *Fusarium* species found in previous studies from other countries (2, 4, 6, 13). Although toenails are commonly affected by *Fusarium* onychomycosis (2), the site of infection in this patient is the fingernail with the lesion of discoloration and onycholysis. DLSO is the most common clinical subtype of *Fusarium* onychomycosis (2), which is also seen in this report. Risk factors for NDMs onychomycosis include climate, age, gender, occlusive footwear, hyperhidrosis, local nail damage, chronic skin illnesses, family history of onychomycosis, occupational exposures, and comorbidities in special

patient populations (diabetes, peripheral vascular disease, and immunosuppression) (6, 7). However, this patient did not exhibit a previous history of all of the above risk factors. Considering to patient’s medical history of taking a contraceptive pill, although the side effects related to fingernail onycholysis have been noticed in a previous publication in 1976 (14), it is not certain that this is an underlying condition in this case since there are the differences in the component of contraceptive drugs in the past and today.

The virulence and pathogenesis of *Fusarium*, including the production of mycotoxins, proteases, and collagenases, as well as fungal biofilm, have been investigated (10, 15). A study of *Fusarium* spp. biofilm by Galletti et al. found that *Fusarium solani* isolated from onychomycosis patients was more virulent than the other *Fusarium* species tested (16). In addition, fungal biofilms are also the factors that make them resistant to disinfection and antifungal drugs (15). Although the result of *Fusarium* antifungal susceptibility testing varies in different studies, the clinical relevance of these in vitro data is not clear (1, 2). The study by Haghani et al. showed that *Fusarium* spp. isolates were susceptible to new triazoles such as luliconazole, lanoconazole, amphotericin B, and voriconazole; in contrast, itraconazole and caspofungin were not effective at all against *Fusarium* (6). In the report of Rosa et al. high MICs values of amphotericin B, voriconazole, itraconazole, and terbinafine were observed for *Fusarium solani* isolates (13). In the present case, *in vitro* testing suggested that this fungal isolate was resistant to itraconazole, voriconazole, caspofungin, and amphotericin B; and was susceptible to terbinafine. The data of antifungal testing from the studies by Haghani (6) and Rosa (13) and from this present report are show in Table 1.

Since *Fusarium* spp. susceptibility varies widely, this demonstrates the importance of antifungal susceptibility testing for selecting the right drug.

Post-treatment follow-up showed that the nail lesion was healed after two months of treatment with terbinafine 250 mg per day for two months, and there was no recurrence after one year, which is consistent with *in vitro* testing.

**CONCLUSION**

We reported successful treatment of *F. solani* onychomycosis with terbinafine supported by antifungal susceptibility testing. It was concluded that sensitivity testing for *Fusarium* nail infection should be implemented to choose appropriate drugs.

**REFERENCES**

1. Gupta AK, Stec N, Summerbell RC, Shear NH, Piguet V, Tosti A, et al. Onychomycosis: a review. *J Eur Acad Dermatol Venereol* 2020; 34: 1972-1990.
2. Uemura EVG, Barbosa MDS, Simionatto S, Al-Harrasi A, Al-Hatmi AMS, Rossato L. Onychomycosis caused by *Fusarium* species. *J Fungi (Basel)* 2022; 8: 360.
3. Chadeganipour M, Mohammadi R. Causative agents of onychomycosis: a 7-year study. *J Clin Lab Anal* 2016; 30: 1013-1020.
4. Noguchi H, Matsumoto T, Kimura U, Hiruma M, Kano R, Yaguchi T, et al. Non-dermatophyte Mould Onychomycosis in Japan. *Med Mycol J* 2020; 61: 23-31.
5. Ribeiro CSDC, Zaitz C, Framil VMDS, Ottoboni TSDC, Tonoli MSDC, Ribeiro RP. Descriptive study of onychomycosis in a hospital in São Paulo. *Braz J Microbiol*

**Table 1.** Antifungal susceptibility profile of *Fusarium* isolated from studies of Haghani, Rosa, and this present case

Species, (No. of isolates)	MIC (µg/ml)										Reference
	Itraconazole		Voriconazole		Amphotericin B		Terbinafine		Caspofungin		
	Range	GM	Range	GM	Range	GM	Range	GM	Range	GM	
<i>Fusarium</i> spp. (n=27)	0.25->16	13.36	0.25-16	1.43	0.016-4	0.85	0.032->4	3.26	0.008->8	4.32	(6)
<i>F. solani</i> (n=3)	1->64	43	0.5->32	8.17	0.125-16	6.71	>64	64	-	-	(13)
<i>F. solani</i> (n=1)	> 8		8		> 8		1		> 8		This present case

(GM: geometric mean MIC).

- 2015; 46: 485-492.
6. Haghani I, Shams-Ghahfarokhi M, Dalimi Asl A, Shokohi T, Hedayati MT. Molecular identification and antifungal susceptibility of clinical fungal isolates from onychomycosis (uncommon and emerging species). *Mycoses* 2019; 62: 128-143.
  7. Gupta AK, Summerbell RC, Venkataraman M, Quinlan EM. Nondermatophyte mould onychomycosis. *J Eur Acad Dermatol Venereol* 2021; 35: 1628-1641.
  8. Diongue K, Ndiaye M, Seck MC, Diallo MA, Badiane AS, Ndiaye D. Onychomycosis caused by *Fusarium* spp. in Dakar, Senegal: epidemiological, clinical, and mycological study. *Dermatol Res Pract* 2017; 2017: 1268130.
  9. Batista BG, Chaves MAD, Reginatto P, Saraiva OJ, Fuentefria AM. Human fusariosis: An emerging infection that is difficult to treat. *Rev Soc Bras Med Trop* 2020; 53: e20200013.
  10. Hof H. The medical relevance of *Fusarium* spp. *J Fungi (Basel)* 2020; 6: 117.
  11. Ngo TMC, Ton Nu PA, Le CC, Vo MT, Ha TNT, Do TBT, et al. *Nannizzia incurvata* in Hue city - Viet Nam: Molecular identification and antifungal susceptibility testing. *J Mycol Med* 2022; 32: 101291.
  12. Guinea J, Meletiadiis J, Arikan-Akdagli S, Muehlethaler K, Kahlmeter G, Arendrup M, et al. EUCAST definitive document E.Def 9.4 Method for the determination of broth dilution minimum inhibitory concentrations of antifungal agents for conidia forming moulds. EUCAST 2022. [https://www.eucast.org/astoffungi/methodsinantifungalsusceptibilitytesting/ast\\_of\\_moulds](https://www.eucast.org/astoffungi/methodsinantifungalsusceptibilitytesting/ast_of_moulds)
  13. Rosa PD, Heidrich D, Corrêa C, Scroferneker ML, Vettorato G, Fuentefria AM, et al. Genetic diversity and antifungal susceptibility of *Fusarium* isolates in onychomycosis. *Mycoses* 2017; 60: 616-622.
  14. Byrne JP, Boss JM, Dawber RP. Contraceptive pill-induced porphyria cutanea tarda presenting with onycholysis of the finger nails. *Postgrad Med J* 1976; 52: 535-538.
  15. Sav H, Rafati H, Öz Y, Dalyan-Cilo B, Ener B, Mohammadi F, et al. Biofilm formation and resistance to fungicides in clinically relevant members of the fungal genus *Fusarium*. *J Fungi (Basel)* 2018; 4: 16.
  16. Galletti J, Tobaldini-Valerio FK, Silva S, Kioshima ÉS, Trierweiler-Pereira L, Bruschi M, et al. Antibiofilm activity of propolis extract on *Fusarium* species from onychomycosis. *Future Microbiol* 2017; 12: 1311-1321.