

## Extensive monomicrobial necrotizing fasciitis and myonecrosis of left hemi trunk in a healthy 41-year-old man with COVID-19 infection

Maryam Sarkardeh<sup>1,2</sup>, Ali Ahmadabadi<sup>1,2</sup>, Zahra Sadrzadeh<sup>2</sup>, Javad Koushki<sup>2</sup>, Amir Esmacili<sup>2</sup>, Sima Davoodi<sup>3</sup>, Mostafa Izanlu<sup>4\*</sup>

<sup>1</sup>Surgical Oncology Research Center, Mashhad University of Medical Sciences, Mashhad, Iran

<sup>2</sup>Department of Surgery, Imam Reza Hospital, Mashhad University of Medical Sciences, Mashhad, Iran

<sup>3</sup>Department of Dermatology, Imam Reza Hospital, Mashhad University of Medical Sciences, Mashhad, Iran

<sup>4</sup>Department of Pathology, Imam Reza Hospital, Mashhad University of Medical Sciences, Mashhad, Iran

Received: March 2022, Accepted: July 2022

### ABSTRACT

Necrotizing fasciitis and myonecrosis caused by *Escherichia coli* is an extremely uncommon infection with a high mortality. We present a case of 41-year-old man with no history of underlying disease one week after covid-19 infection, who was admitted with symptoms of Fournier's gangrene and then *E. coli*-induced monomicrobial necrotizing fasciitis.

**Keywords:** Necrotizing fasciitis; COVID-19; *Escherichia coli*; Vacuum-assisted closure

### INTRODUCTION

Coronavirus Disease 2019 (COVID-19), caused by the SARS-CoV-2 virus, is a significant health concern and can be deeply harmful. The COVID-19 epidemic calls for worldwide special attention to develop effective treatments, including effective drugs and vaccines. However, the most patients are currently treated with supportive treatments, such as oxygen supply, and antiviral drugs and corticosteroids (1).

Necrotizing fasciitis is a quickly progressive tissue necrosis of skin, soft tissue and muscles that is associated with significant complications and mortality. The rapid identification of necrotizing fasciitis is essential in reducing the associated mortality (2). Some associated diseases, such as diabetes, immunodeficiency, trauma, hematological diseases, or cirrhosis

of the liver, increase the risk of this infection (3).

Necrotizing fasciitis is classified as type 1 (polymicrobial), type 2 (monomicrobial caused by group A  $\beta$ -hemolytic streptococci or *S. aureus*), type 3 (monomicrobial caused by Gram-negative bacilli including *Escherichia coli*) and type 4 (fungal infection) (4).

Underlying coronavirus infection 19 (COVID-19) may increase the risk of secondary infections, including necrotizing fasciitis, and may affect its treatment (5). Clinical manifestations of necrotizing fasciitis show a range of symptoms; hence timely diagnosis and treatment is a significant challenge (6). Managing necrotizing fasciitis associated with COVID-19 infection may be challenging. COVID-19 can increase the risk of secondary infections by creating lymphopenia and it can make the condition of patients worse (7).

\*Corresponding author: Mostafa Izanlu, MD, Department of Pathology, Imam Reza Hospital, Mashhad University of Medical Sciences, Mashhad, Iran. Tel: +98-9151872367 Email: mostafa.izanlu@gmail.com

We report an unexpected case a week after the COVID-19 infection. He underwent surgery with symptoms of perianal abscess and Fournier's gangrene, and four days after being discharged from the hospital, he went to the emergency room with symptoms of necrotizing fasciitis on the left side and was referred to the operating room for reoperation, and survived miraculously with timely surgery and proper postoperative care.

## CASE REPORT

The patient was a 41-year-old man with severe fever and chilling referred to the Emergency Department of Imam Reza Hospital in Mashhad, Iran. He had suffered from pain and erythema of the perineum and scrotum skin for three days. He tested positive for COVID-19 a week before an emergency visit, was confirmed by polymerase chain reaction (PCR), and has been treated with four doses of dexamethasone 4mg intra muscular (IM) per day. The patient did not mention any history of underlying diseases such as diabetes mellitus, hypertension, smoking and trauma.

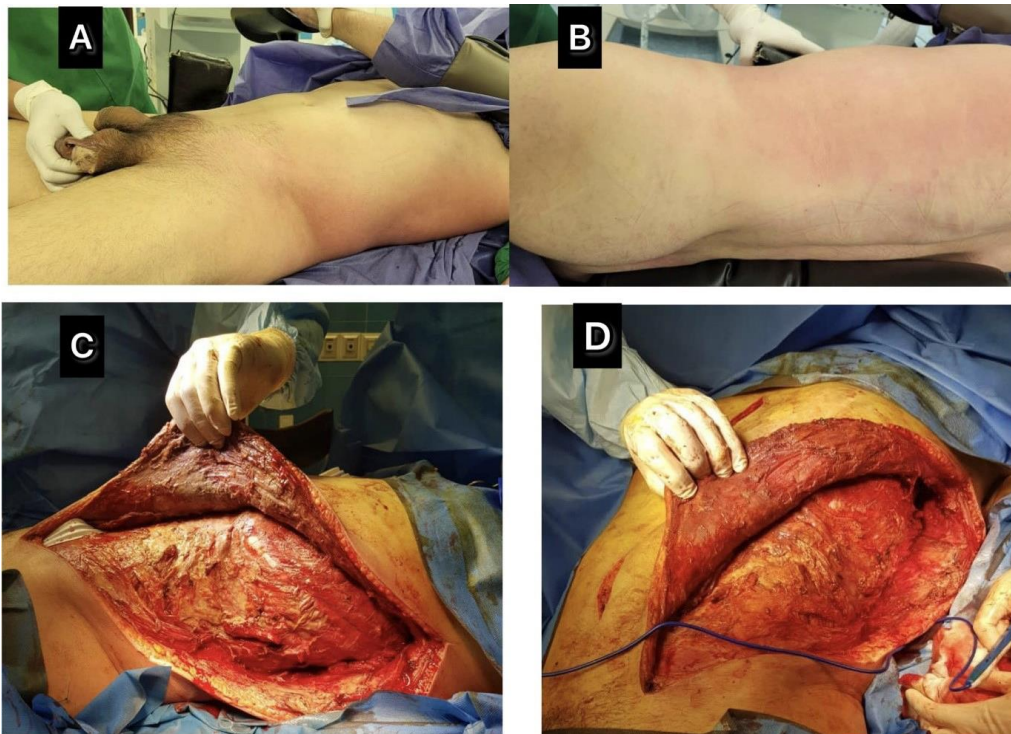
In the examination, the patient was not generally well and had toxic symptoms. Vital signs on admission time were follows: blood pressure (BP) 90/70 mm Hg, pulse rate (PR) 120/min, temperature 38.3°C (oral), and oxygen saturation (SpO<sub>2</sub>) 96% in room air, fasting blood sugar (FBS) 142 mg/dl, the patient had fecal retention in the past three days due to pain during defecation. Perineum and scrotum skin was touch-sensitive. Laboratory studies showed leukocytosis with white blood cell (WBC)  $14.2 \times 10^3$   $\mu$ l, lymphocytopenia (lymphocyte count 710 cells/ $\mu$ l), ferritin level 375 ng/mL, and a high level of C-reactive protein. Electrolytes, renal parameters and liver function tests were normal. Ultrasound was performed, and showed a thick, edematous scrotal wall containing hyperechoic foci, indicating gas inside the wall of the scrotum and perineum and infective-inflammatory collection within the perianal region. The patient underwent debridement and abscess drainage in urology service with the recognition of Fournier Gangrene, probably following perianal abscess. The result of the patient's tissue culture in the first hospitalization was a multi-microbial infection sensitive to cefepime, ceftazidime, ceftriaxone, vancomycin, imipenem, gentamicin and resistant to ciprofloxacin

and cotrimoxazole. The patient was treated with vancomycin and imipenem antibiotics for 7 days and was discharged from the urology services in good general condition.

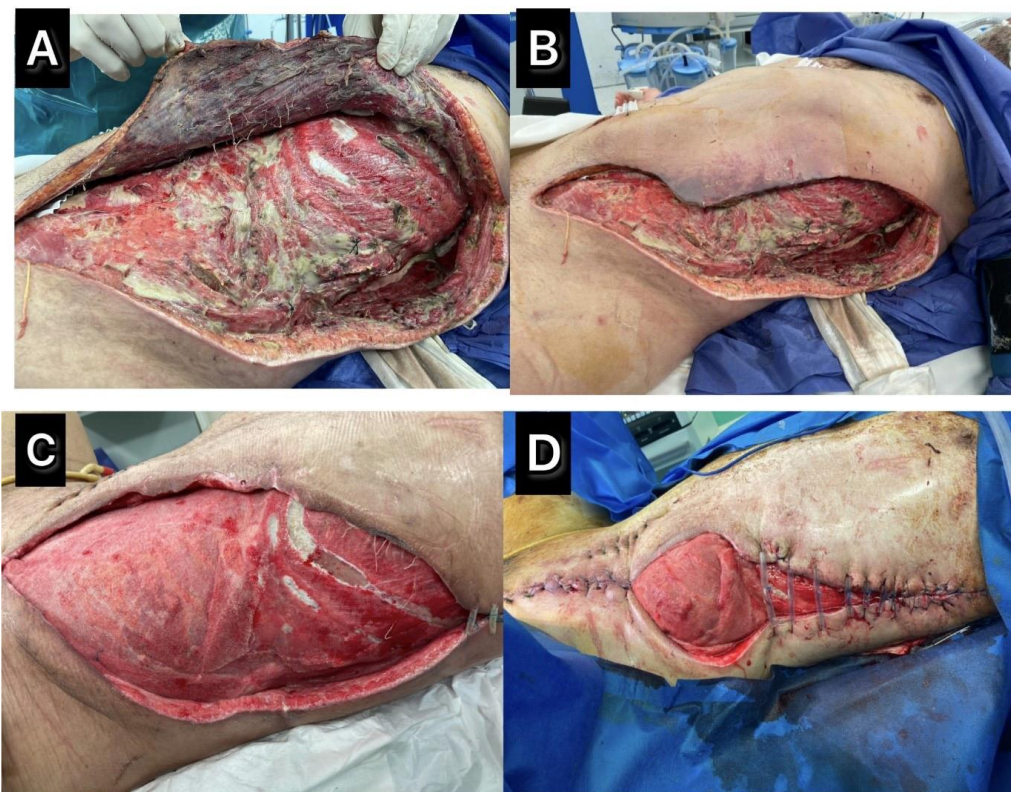Four days after being discharged from the hospital, despite the treatment of surgery and appropriate antibiotics, the patient suffered from rapidly progressing pain and redness on the left side of his abdomen and thorax, sensitive to touch and crepitation in palpation (Fig. 1). The patient underwent re-ultrasound emergency and had shown the thickening of fascial and subcutaneous tissues, and subcutaneous air were shown.

The patient has referred again to the operating room and underwent extensive debridement (Fig. 1), and continuous wound irrigation with normal saline and antibiotic therapy for 14 days (Fig. 2). Microscopic findings including coagulative and liquefactive necrosis in subcutaneous adipose tissue and striated muscles with extensive inflammatory cells infiltration was a mixture of neutrophils and lymphocytes (Fig. 3). *E. coli* strain was isolated from blood and tissue cultures. Antibiotics were changed to penicillin G, piperacillin-tazobactam and vancomycin according to infectious specialist consult.

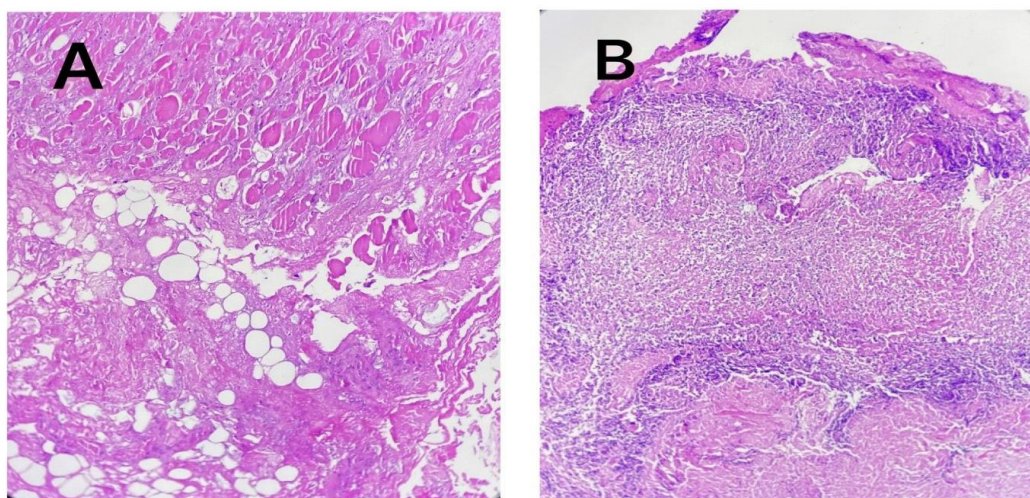
After complete control of the infection and ensuring no disease progression, the patient was a candidate for Vacuum-assisted wound closure (VAC) (Fig. 2). Due to the extent of the wound in the abdomen, and thorax, a sterile reticulated polyurethane sponge has been cut to conform with the surface of the wound and then is placed into the wound to make contact with the entire wound surface and then a central cup collector drain with two silicone nelaton Catheter inserted into the sponge placed on its surface without damage to the granulation tissue was done. Two washing ways was placed by the infusion set in the upper and lower part of the wound, which continuously washed the surface with half a liter of normal saline and 250 ml of acetic acid solution 2%, antiseptic prontosan irrigation solution (anti-biofilm) and used topical regular insulin for accelerated healing. The patient was intermittently every 4-3 days under vacuum replacement and wound washing in the operating room. After preparing the bed of the wound gradually started to shrink the defect created using sutures, and after 35 days, the patient underwent skin grafts (Fig. 4). Then, he was released from our hospital in good general condition and returned to his life.



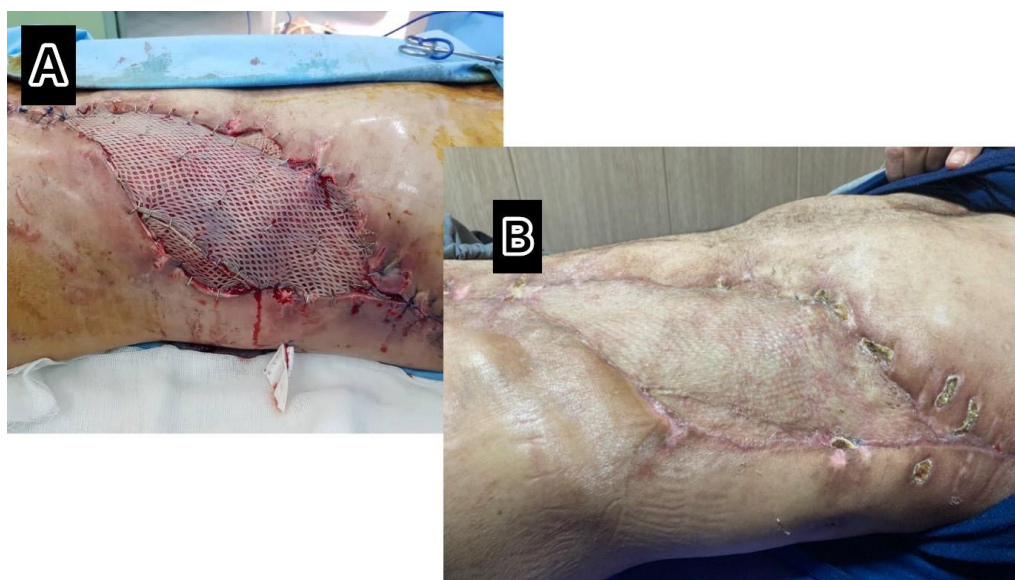**Fig. 1.** A, B: preoperative erythema and crepitation that originated from the perianal abscess and extended to the left inguinal canal, left side of his abdomen, and thorax. C, D: first-time debridement in the operation room



**Fig. 2.** A, B: debridement and wound irrigation after seven days. C: wound condition and granulation tissue formation after 14 days and vacuum-assisted wound therapy D: wound condition after 28 days



**Fig. 3.** A: Coagulative and liquefactive necrosis in subcutaneous adipose tissue and striated muscles. B: Extensive exudate was a mixture of neutrophils and lymphocytes



**Fig. 4.** A: Skin grafting after 35 days. B: Final result after 60 days

## DISCUSSION

Necrotizing fasciitis is a rare soft tissue infection associated with necrosis edema with a mortality rate of 50-70% (8). We are presenting a case that had widespread with rapidly progressive and unexpected expansion necrotizing fasciitis of the scrotum and perineum (Fournier's Gangrene) to half of abdomen and trunk by monomicrobial infection *E. coli* strain after COVID-19 infection and taking four doses of dexamethasone.

Necrotizing fasciitis caused by *E. coli* is a rare occurrence, and despite antimicrobial therapy and

surgical debridement, mortality is still high. Chen et al. showed that among 126 patients with necrotizing fasciitis caused by *E. coli*, only in 2 patients (1.6%) were found as a monomicrobial agent (9). Necrotized fasciitis due to *E. coli* has been reported in infants following surgery (10) or Iron-Overloaded (11). Nazir et al. noted that one of the factors that enhanced microbial virulence and increased *E. coli* proliferation is iron overload (11).

Habib et al. (2021) suggest that the key virulence stage of COVID-19 is an attack on the hemoglobin molecule, which causes porphyrins to separate from iron and increases iron in circulation. Therefore, ox-

xygen cannot bind to hemoglobin molecule and which creates a fatal condition by causing rapid multi-limb failure. In addition, free iron released in circulation may lead to iron overload, which causes oxidative damage to cells and may also cause increased inflammation and dysfunction of the immune system. This increase in iron absorption and storage is likely to lead to an increase in ferritin concentrations (iron storage molecules in the body) in the circulation of COVID-19 patients (12), as reported by our case. Also, COVID-19 can increase the risk of secondary infections by creating lymphopenia (7).

All of the above-mentioned cases, such as increased ferritin level in COVID-19 patients, the role of iron in enhanced microbial virulence and increased *E. coli* proliferation, lymphopenia caused by COVID-19 infection, probably can explain the unexpected expansion of necrotizing fasciitis in our patient.

Necrotizing fasciitis associated with *E. coli* has a bad prognosis, and almost all cases are fatal in the adult population. Shaked et al. (13) reported, seven patients from a hospital had necrotizing fasciitis associated with *E. coli*, but in contrast to our patient, each one had some form of immunodeficiency, and all had a fatal result. Similar to the current case report, successful treatment with timely surgical debridement, strong proprietary antimicrobial therapy, and invasive supportive care such as Vacuum-assisted wound closure (VAC) has been reported in some infant and adult patients (10, 14).

## CONCLUSION

Considering that necrotizing fasciitis management is a critical challenge, immediate surgical treatment can improve the outcomes of patients with such conditions. As was said about our patient, timely diagnosis, procedures, and postoperative care, specially choosing correct antibiotics and vacuum therapy, can lead to the remarkable recovery of the patient been referred with the fatal spread of infection. Therefore, health care systems should pay special attention to this disease during the COVID-19 pandemic.

## ACKNOWLEDGEMENTS

The authors would like to thank Mashhad University of Medical Sciences for financial support.

## REFERENCES

- Rodriguez-Guerra M, Jadhav P, Vittorio TJ. Current treatment in COVID-19 disease: a rapid review. *Drugs Context* 2021; 10: 2020-10-3.
- Stevens DL, Bryant AE. Necrotizing soft-tissue infections. *N Engl J Med* 2017; 377: 2253-2265.
- Keung EZ, Liu X, Nuzhad A, Adams C, Ashley SW, Askari R. Immunocompromised status in patients with necrotizing soft-tissue infection. *JAMA Surg* 2013; 148: 419-426.
- Elliott D, Kufera JA, Myers RA. The microbiology of necrotizing soft tissue infections. *Am J Surg* 2000; 179: 361-366.
- Elashry MM, Alagha M, Salama M. Pre and retroperitoneal necrotizing fasciitis after COVID-19 infection: A case report. *Radiol Case Rep* 2021; 16: 2949-2952.
- Misiakos EP, Bagias G, Patapis P, Sotiropoulos D, Kanavidis P, Machairas A. Current concepts in the management of necrotizing fasciitis. *Front Surg* 2014; 1: 36.
- Lee J, Park S-S, Kim TY, Lee D-G, Kim D-W. Lymphopenia as a biological predictor of outcomes in COVID-19 patients: a nationwide cohort study. *Cancers (Basel)* 2021; 13: 471.
- Hakkarainen TW, Kopari NM, Pham TN, Evans HL. Necrotizing soft tissue infections: review and current concepts in treatment, systems of care, and outcomes. *Curr Probl Surg* 2014; 51: 344-362.
- Chen IC, Li W-C, Hong Y-C, Shie S-S, Fann W-C, Hsiao C-T. The microbiological profile and presence of bloodstream infection influence mortality rates in necrotizing fasciitis. *Crit Care* 2011; 15: R152.
- Barker L, Pringle K, Cusack J. Necrotising fasciitis with *Escherichia coli* in a newborn infant after abdominal surgery. *Arch Dis Child Fetal Neonatal Ed* 2013; 98: F404.
- Nazir H, Al Yazidi L, Mutani M, Zachariah M. *E. coli* monomicrobial necrotizing fasciitis in an iron-overloaded adolescent. *Pediatr Infect Dis J* 2020; 39(4): e40-e41.
- Habib HM, Ibrahim S, Zaim A, Ibrahim WH. The role of iron in the pathogenesis of COVID-19 and possible treatment with lactoferrin and other iron chelators. *Biomed Pharmacother* 2021; 136: 111228.
- Shaked H, Samra Z, Paul M, Madar-Shapiro L, Cohen J, Pitlik S, et al. Unusual "flesh-eating" strains of *Escherichia coli*. *J Clin Microbiol* 2012; 50: 4008-4011.
- Webb LX. New techniques in wound management: vacuum-assisted wound closure. *J Am Acad Orthop Surg* 2002; 10: 303-311.