

The effects of heat-killed *Tsukamurella inchonensis* on intestinal morphology and humoral immune responses of broiler chickens

Katayoon Nofouzi^{1*}, Sorayya Mirzazadeh¹, Monireh Khordadmehr¹, Mohammad Sadegh Madadi²,
Soheila Amininia³, Masoumeh Firouzamandi¹, Vahid Reza Ranjbar⁴

¹Department of Pathobiology, Faculty of Veterinary Medicine, University of Tabriz, Tabriz, Iran

²Department of Clinical Sciences, Faculty of Veterinary Medicine, University of Tabriz, Tabriz, Iran

³Department of Serology, Iran Veterinary Organization, East Azerbaijan, Iran

⁴Department of Poultry Diseases, Veterinary System Organization, Yazd Province, Yazd, Iran

Received: June 2020, Accepted: November 2020

ABSTRACT

Background and Objectives: *Tsukamurella* species are Gram-positive rods that exist in a broad range of environments. In this study, the efficacy of heat-killed *Tsukamurella inchonensis* on growth performance, intestinal morphology, and humoral immune responses of broiler chicken was evaluated.

Materials and Methods: Ross broiler chicks in the cage were randomly allocated to five groups. Trail diets were prepared by adding 10⁶ cells per bird of heat-killed *T. inchonensis* into the basal trading diet for group 1 continuously dosed for 24 h from day 1 to day 13, and for group 2, 24 h on days 1 to 5; 8; 9, 12 and 13. Group 3 was received 10⁶ bacteria as a subcutaneous injection on days 1, 6, and 12. Groups 4 and 5 were not received *T. inchonensis* during the experiment period.

Results: Feed intake (FI) and feed conversion ratio (FCR) were not altered by different delivery methods of *T. inchonensis* supplementation. The pulsed dosed in feed tended to provide higher body weight gain (BWG) than the negative control groups. *T. inchonensis* treatments, never less of the ways of delivery, boosted (P<0.05) the antibody titers to Newcastle disease virus (NDV), and avian influenza (AI) (H9N2) virus, especially when broiler chickens treated with pulse dosed in the feed. The most significant intestinal development (p<0.05) was observed between groups 1 and 2. There were no significant differences in the thymus, liver, and bursa of Fabricius relative weight. Still, there were significant increases in the relative weight of spleen on day 14 in vaccinated chickens treated with *T. inchonensis* pulse dosed.

Conclusion: It seems that the supplementation of *T. inchonensis* in the broiler diet can improve intestinal morphology and humoral immune response, which was represented by increased antibody response to NDV, and AI vaccines significantly, but it cannot affect FI and FCR.

Keywords: Actinomycetales; *Tsukamurella inchonensis*; Chickens; Immune response; Humoral; Avian influenza; Newcastle disease virus

INTRODUCTION

Unreasonable usage of antibiotics as a growth promoter and as therapeutic agents in livestock and poultry is a significant issue (1). The development of a rational replacement of medicines to control microbial diseases is under consideration (2). Detecting

*Corresponding author: Katayoon Nofouzi, Ph.D, Department of Pathobiology, Faculty of Veterinary Medicine, University of Tabriz, Tabriz, Iran.
Tel: +98-4136378734
Fax: +98-4136378744
Email: nofouzi@tabrizu.ac.ir

new antigens along with adjuvants is the most helpful method to get a choice protecting immunity against poultry diseases such as Newcastle disease (ND) and avian influenza (AI), that produce notable economic troubles in poultry global (3).

Investigations have manifested that bacterial immunomodulators based on aerobic Actinomycetales can significantly affect on infectious procedures, clinically evident or not, and inflammatory response (4). More recently, several other aerobic Actinomycetes species, counting *Rhodococcus coprophilus* (Rc), *Gordinia bronchialis* (Gb), and *Tsukamurella inchonensis* (*T. inchonensis*), firmly associated with mycobacteria, which are able of exerting various strong adjuvant or immunomodulatory actions when inoculated as suspensions of killed bacilli, have been identified (5).

Choosing a microorganism that has helpful actions in broiler chickens needs a broad examination for the chosen candidate, and one that will act under experimental situations. There are many distinct approaches for administering microorganisms to broiler chickens. Through the feed, water, gavage, injection, but adding them to the feed is the most frequently used approach in the poultry management.

Vaccination for protecting chickens from ND and AI is routinely practiced throughout the world (6). Although, vaccines have been shown to occasionally provoke inadequate immune responses due to vaccine failure (7). Consequently, the usage of immunomodulators to boost the immune function in broiler chicks has been recognized as a potent means of enhancing the poultry management (8).

Since it was proven that *T. inchonensis* has practical effects on Japanese quail (9), we decided to work on the effects of this reagent on broiler chickens. Regarding the practical effects of Actinomycetales species on the treatment of asthma and sweet-itch (10) and also improvement of immune responses to gather with the intestinal activity in mice (4), the present examination aimed to evaluate the impacts of *T. inchonensis* on the development of antibodies in sera and intestinal function of broiler chickens.

MATERIALS AND METHODS

Ethical approval. The research was performed under the approval of the ethic committee on animal ethics, University of Tabriz, Tabriz, Iran (2018/939),

and the recommendations of the European Council Directive (86/609/EC) of November 24, 1986.

Experimental model. Firstly, cultured and heat-killed *T. inchonensis* by autoclaving was achieved from BioEos Ltd (Kent, UK). Then, 180 one-day-old Ross broiler chicks were randomly selected in five equal groups, as shown in Table 1. The bird management was consistent with the guidance of the Ross broiler commercial management guide (www.aviagen.com). Briefly, three corn-soybean based basal diets were prepared to be fed during starter (day 1 to day 14), growing (day 14 to day 28), and finishing (day 28 to day 42) phases. Food and clean drinking water were provided ad libitum during the trial. Diets were fed in mash form. The vaccination was conducted for all of the groups except group 5 by combined oil emulsion inactivated influenza (H9N2) and Newcastle (V4) vaccine (NewFluRazi, inactivated, oil-based ND & AI vaccine, Razi, Iran) subcutaneously on day seven, and LaSota vaccine (live freeze-dried, Razi, Iran) on day 18, as an eye drop. In group 5, no vaccination with no bacteria treatment was considered. Experimental diets were prepared by adding 10^6 cells/day/bird of heat-killed *T. inchonensis* into the commercial basal diet for groups 1 and 2.

Growth performance. Feed residues and birds were weighed weekly for the estimation of daily average feed intake (FI) and body weight gain (BWG). Mortality was noted when it appeared, and feed conversion ratio (FCR= FI/BWG) was corrected for mortality (11).

Sample collection. Blood was collected on days 1, 14, 28, and 42 from the wing vein of 12 birds, randomly per treatment. The sera were collected by centrifugation and stored (-20°C) before analysis. Besides, at days 14, 28, and 42, five chicks from each cage were randomly selected and slaughtered for histological studies. Moreover, the visceral organs comprising the thymus, spleen, liver, and bursa of Fabricius were weighed and noted, independently. In biological research work, sampling errors must also be considered. However, in the present study, due to the appropriate sample size, this error has been reduced.

The relative weight of lymphoid organs. The immune organ relative weight was calculated using the

Table 1. The experimental design was performed in the presented study (n = 36).

Experimental groups	Treatment
Group 1	Vaccination + oral administration of Ti * at the days 1-13 continuously
Group 2	Vaccination + oral administration of Ti * at the days 1-5, 8, 9, 12, 13
Group 3	Vaccination + subcutaneous injection of Ti at the days 1, 6, 12
Group 4	Vaccination + no bacteria treatment
Group 5	No Vaccination + no bacteria treatment

Ti: *Tsukamurella inchonensis* with 10^6 cells/day/bird

following formula: relative weight of immune organ = immune organ weight (g)/body weight (g) \times 100% (12).

Antibody titer against ND and AI vaccines. Serum ND and AI antibody titer were studied in days 1, 14, 28, and 42, by ELISA, which measured by double-antibody sandwich ELISA using commercial kits (IDEXX, France) according to the manufacturer's guidance.

Histological examination. The tissue samples of the liver, kidney, heart, and brain were studied for hepatotoxicity, nephrotoxicity, cardiac toxicity, and neurotoxicity of *T. inchonensis*, respectively. Moreover, the small intestine (including duodenum, jejunum, and ileum), and caecal tonsil were taken for histomorphometric study. The tissues were fixed in 10% buffered formalin, processed routinely, sectioned at about 5 μ m, stained by hematoxylin-eosin (H&E), and eventually studied microscopically by a light microscope (OLYMPUS-CH30, Japan). The intestinal morphology was evaluated as previously described (13, 14), using a microscopic calibrated lens (PF10X lens), which included: villus height (measured from the villus-crypt junction), villus thickness (measured at mid-villus height), intestinal crypt depth (measured from the villus-crypt junction until the end of glands), intestinal crypt number and goblet cells number. Also, for comparative evaluation of caecal tonsil improvement, the relative lymphoid area of caecal tonsil to entire caecal tonsil circumference, height, and thickness of nodular unit fold was measured microscopically (15).

Statistical analysis. The results were expressed as means \pm standard deviation (SD), statistically analyzed by One-Way ANOVA, and the Tukey post-hoc tests. Differences were considered significant at $p < 0.05$.

RESULTS

Growth performance. FI and FCR were not altered by various delivery approaches of *T. inchonensis* supplementation. The pulsed dosed in feed tended to provide higher BWG than the negative control groups (Table 2).

Lymphoid organ weight. There were no significant differences in thymus, liver, and bursa of Fabricius relative weight, but there was a significant increase in spleen relative weights on day 14 in the second group.

Antibody titer. Antibody titers against ND vaccination of the broiler chickens of different experimental groups are presented in Fig. 1. As presented in the Table 2, the maternally derived antibody (MDA) of the birds gently reduced in the fifth group. Antibody titers of vaccinated broilers started to enhance at the end of the 28 days, while those of unvaccinated birds were steadily reduced. Notably, the highest levels of the antibody titers of the vaccinated chickens were observed on day 42 of age in the second group, which significantly differs when compared with the fourth group (Fig. 1).

Antibody titers against AI vaccination of the chickens are represented in Fig. 2. In the control group, the MDA gradually decreased and reached undetectable levels on day 42 of age. At the same time, those of vaccinated chickens enhanced steadily subsequent vaccination and reached the highest level at six weeks of age (around 37 days post-inoculation). Antibody titers of group 2 had a higher level compared to those of only a vaccinated group (group 4), although around day 42 differences between *T. inchonensis* treated groups and the untreated groups are significant (Fig. 2).

Table 2. The effect of the administration of heat-killed *T. inchonensis* on the performance parameters.

Sampling day	Parameter	Experimental groups				
		1	2	3	4	5
14	BWG	444 ± 25.7 ^{ab}	458 ± 15.1 ^a	440 ± 25 ^{ab}	439 ± 26 ^{ab}	428 ± 22.6 ^b
	FI	498 ^a	515 ^a	546 ^a	536 ^a	525 ^a
	FCR	1.12 ^a	1.125 ^a	1.24 ^a	1.22 ^a	1.22 ^a
28	BWG	1364 ± 110 ^{abcd}	1456 ± 122 ^{acd}	1306 ± 121 ^{bcd}	1272 ± 115 ^{abc}	1294 ± 121 ^{abd}
	FI	1958 ^a	2054 ^a	1987 ^a	1937 ^a	1966 ^a
	FCR	1.43 ^a	1.41 ^a	1.52 ^a	1.522 ^a	1.51 ^a
42	BWG	2649 ± 199 ^{ab}	2724 ± 190 ^a	2515 ± 193 ^{ab}	2461 ± 199 ^b	2508 ± 210 ^{ab}
	FI	4558 ^a	4578 ^a	4632 ^a	4710 ^a	4690 ^a
	FCR	1.72 ^a	1.68 ^a	1.84 ^a	1.91 ^a	1.87 ^a

BWG: body weight gain (mean ± SD, g/bird); FI: feed intake (g/bird); FCR: feed conversion ratio.

a, b, c, d: values within a row followed by different letters are significantly different (P<0.05).

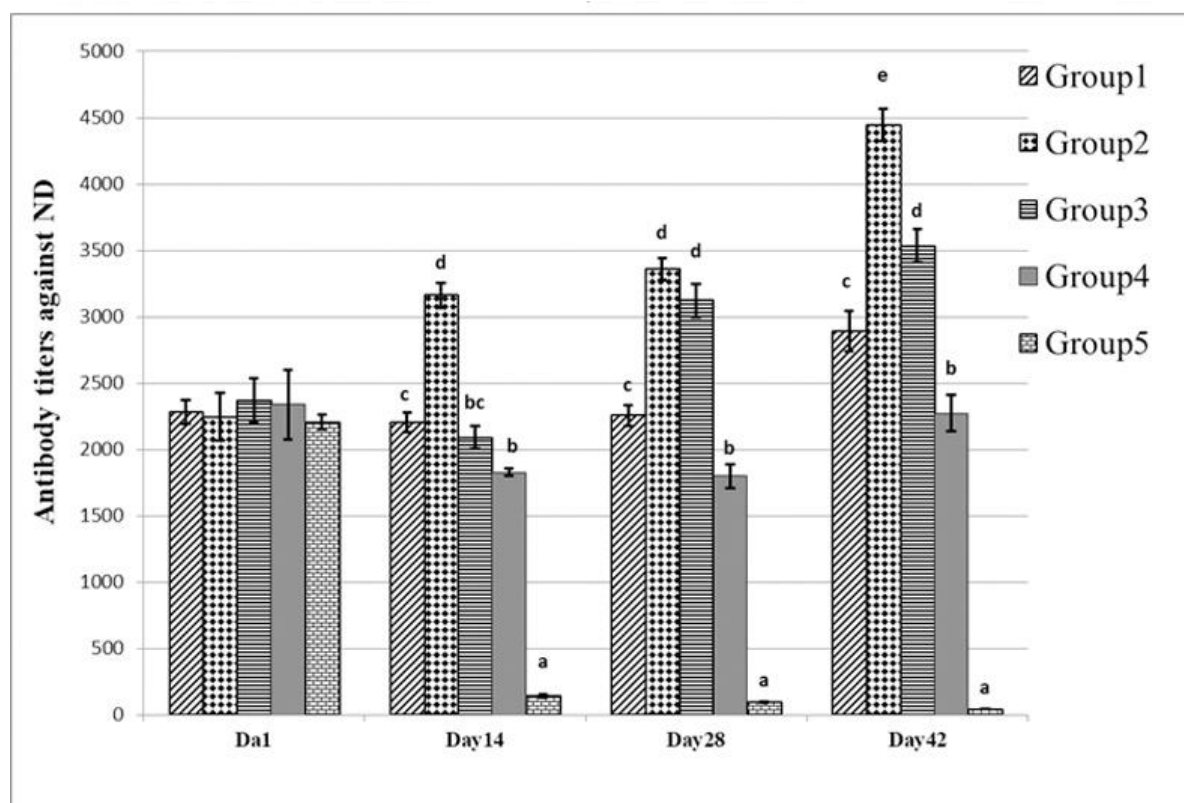


Fig. 1. The effect of the administration of heat-killed *T. inchonensis* on the antibody titers against ND vaccine (Mean ± SEM). Group 1 (Vaccination + oral administration of Ti* at the days 1-13 continuously); Group 2 (Vaccination + oral administration of Ti* at the days 1-5, 8, 9, 12, 13); Group 3 (Vaccination + subcutaneous injection of Ti at the days 1, 6, 12); Group 4 (Vaccination + no bacteria treatment); Group 5 (No Vaccination + no bacteria treatment).

a, b, c, d, e: values within a column followed by different letters are significantly different between groups (P<0.05).

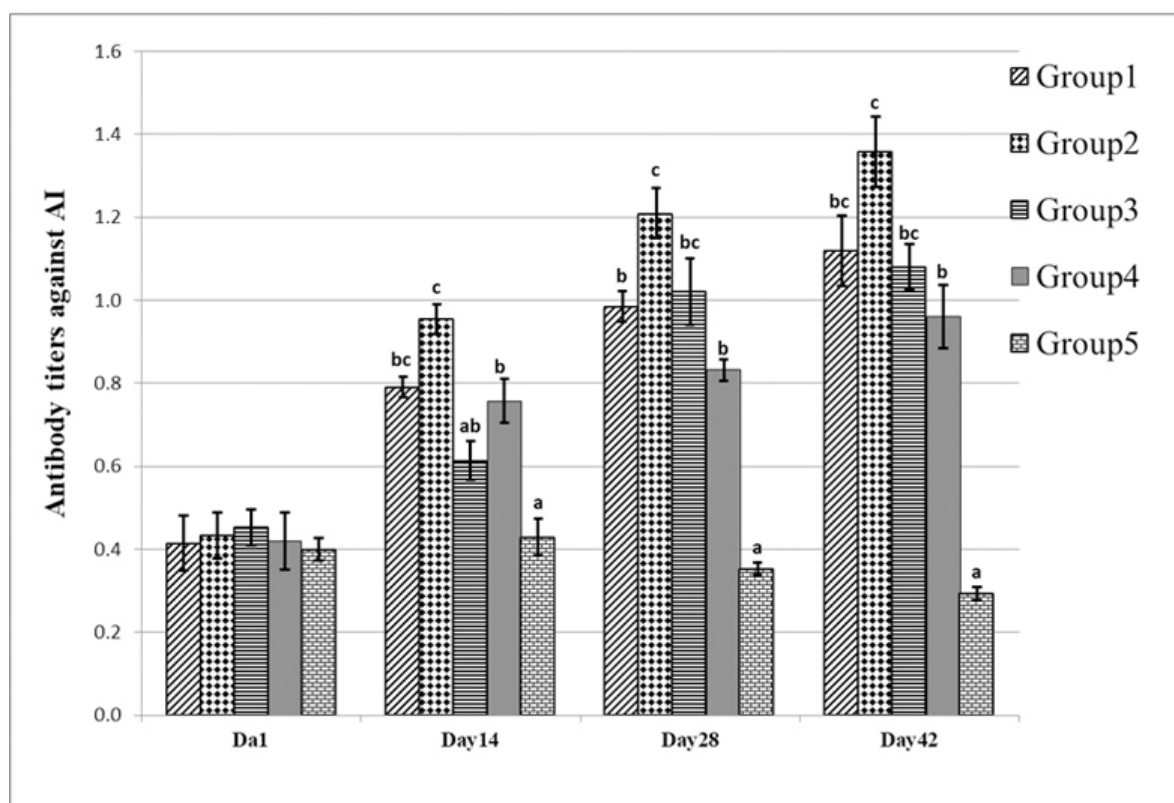


Fig. 2. The effect of the administration of heat-killed *T. inchonensis* on the antibody titers against AI vaccine (Mean ± SEM). Group 1 (Vaccination + oral administration of Ti* at the days 1-13 continuously); Group 2 (Vaccination + oral administration of Ti* at the days 1-5, 8, 9, 12, 13); Group 3 (Vaccination + subcutaneous injection of Ti at the days 1, 6, 12); Group 4 (Vaccination + no bacteria treatment); Group 5 (No vaccination + no bacteria treatment). a, b, c, d: values within a column followed by different letters are significantly different between groups ($P < 0.05$).

Histomorphological findings. Microscopically, there were no toxic or other side effects in the liver, kidney, heart, and brain, respectively. As more details, there were not hemorrhage, vascular congestion, cell swelling, and necrosis in the tissue sections. The histomorphometric measurement results of different parts of the small intestine and lymphoid tissue of caecal tonsil are shown in Figs. 3 and 4. Briefly, the most morphological changes were found between the first and second groups ($P < 0.05$). Notably, these were observed more on the 14 days of sampling compared to the 28 and 42 days ($P < 0.05$). Interestingly, jejunum showed the most considerable morphological changes in different days of sampling ($P < 0.05$). Moreover, intestinal crypt depth, intestinal crypt number and goblet cell number showed more remarkable differences between different experimental groups ($P < 0.05$).

In caeca tonsil, there was a significant difference at all three sampling days in the relative of the lymphoid

to entire circumference and even in the thickness of nodular unit fold in group 5 compared with groups 1, 3, 4, and also between groups 2, 3, 4 ($P < 0.05$). However, the height of the nodular unit fold showed significant differences at 14, and 28 days of age ($P < 0.05$) (Tables 3-5).

DISCUSSION

In this study, the effect of *T. inchonensis* on growth performance, organs weight, and antibody titer of AI and ND of broiler chickens compared to the control group were examined at 14, 28, and 42 days post-challenge with *T. inchonensis*. Compared to *T. inchonensis* delivered via different methods, bacteria, did not significantly affect growth performance or feed conversion in broiler chickens. The bacteria, when given via pulsed dosed in feed achieved the highest weight gain (2724 g) during the 42 d of the

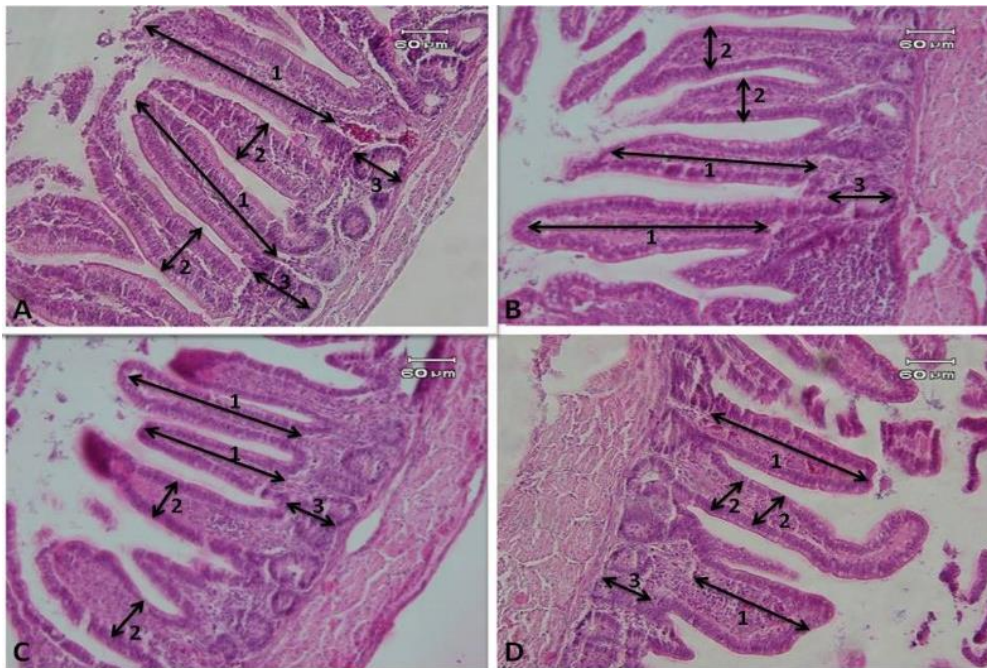


Fig. 3. Small intestine, broiler chicken. Jejunum showed the most significant morphological changes in different days of sampling, mainly when it was used orally. A: first group (vaccination + oral administration of Ti for 1-13 days continuously); B: second group (vaccination + oral administration of Ti on days 1-5, 8, 9, 12, 13); C: third group (vaccination + subcutaneous injection on Ti for days 1, 6, 12); D: control group (no vaccination, no treatment). 1: intestinal villus height; 2: intestinal villus thickness; 3: intestinal crypt depth. H&E.

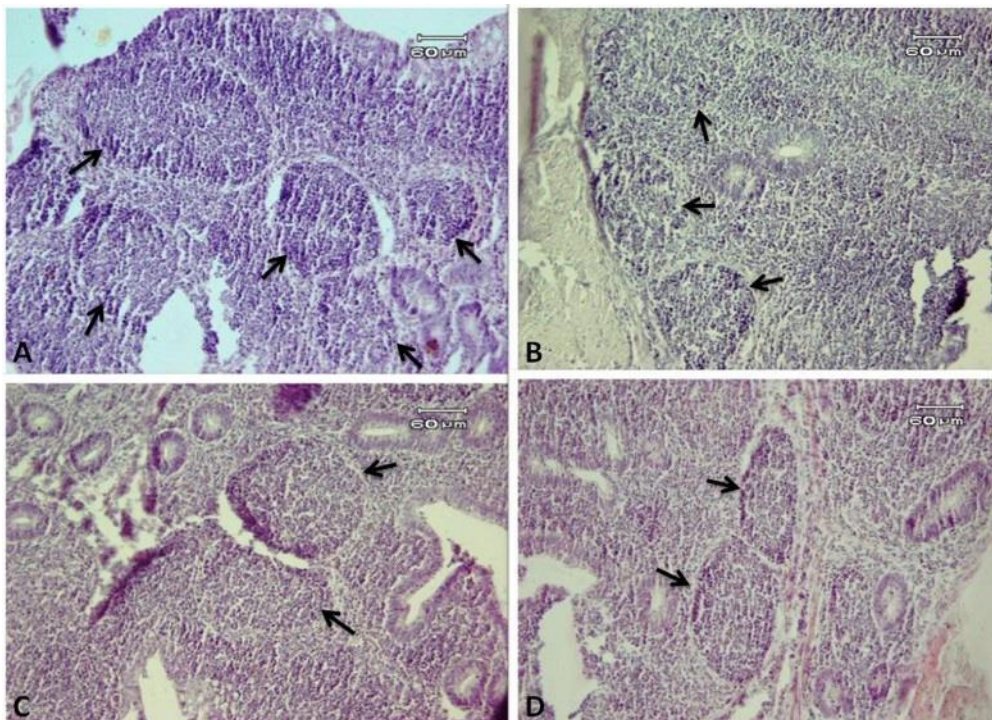


Fig. 4. Cecum (caecal tonsil), broiler chicken. There were the significant differences in the number and thickness of lymphoid follicles at control group compared with other treated groups. A: first group (vaccination + oral administration of Ti for 1-13 days continuously); B: second group (vaccination + oral administration of Ti on days 1-5, 8, 9, 12, 13); C: third group (vaccination + subcutaneous injection on Ti for days 1, 6, 12); D: control group (no vaccination, no treatment). H&E.

Table 3. Effects of different routes of administration of *T. inchonensis* on villus height (μm), villus thickness (μm) and goblet cells number (in 1 mm length) in small intestine of broiler¹ on the 14 days old (the means \pm SEM)

Parameter	Part of intestine	Experimental groups				
		1	2	3	4	5
Villus height	Duodenum	6.10 \pm 0.070 ^c	4.74 \pm 0.140 ^b	3.50 \pm 0.160 ^a	3.80 \pm 0.100 ^a	3.90 \pm 0.070 ^a
	Jejunum	6.80 \pm 0.100 ^c	5.26 \pm 0.110 ^b	4.44 \pm 0.067 ^a	4.56 \pm 0.097 ^a	4.20 \pm 0.110 ^a
	Ileum	4.60 \pm 0.150 ^b	4.24 \pm 0.102 ^b	3.26 \pm 0.140 ^a	3.36 \pm 0.074 ^a	3.24 \pm 0.081 ^a
Villus thickness	Duodenum	1.98 \pm 0.070 ^b	1.62 \pm 0.080 ^b	1.24 \pm 0.080 ^a	1.30 \pm 0.05 ^a	1.36 \pm 0.060 ^a
	Jejunum	2.14 \pm 0.120 ^b	2.10 \pm 0.100 ^b	1.52 \pm 0.120 ^a	1.66 \pm 0.092 ^a	1.60 \pm 0.100 ^a
	Ileum	1.88 \pm 0.058 ^c	1.94 \pm 0.067 ^c	1.54 \pm 0.092 ^b	1.32 \pm 0.058 ^a	1.44 \pm 0.067 ^{ab}
Goblet cells number	Duodenum	89.2 \pm 1.49 ^c	84.8 \pm 1.71 ^b	72.8 \pm 1.39 ^a	71.8 \pm 2.51 ^a	72.0 \pm 2.09 ^a
	Jejunum	93.8 \pm 1.15 ^c	88.8 \pm 1.35 ^b	76.2 \pm 1.71 ^a	72.8 \pm 1.65 ^a	73.4 \pm 1.43 ^a
	Ileum	158 \pm 7.13 ^c	119 \pm 4.57 ^b	95.2 \pm 2.03 ^a	92.0 \pm 3.91 ^a	95.8 \pm 2.74 ^a

^{a-d}Means within a row with no common superscripts differ significantly ($P \leq 0.05$).

1= Vaccinated group "treated with 10^6 *T. inchonensis* continuously dosed in feed from day 1 to day 13. 2: Vaccinated group "treated" with 10^6 *T. inchonensis* pulse-dosed in feed on days 1 to 5; 8 & 9 and 12 & 13. 3: Vaccinated group "treated" with 10^6 *T. inchonensis* by subcutaneous injection on days 1, 6 and 12. 4: Vaccinated group untreated, but injected with carrier (phosphate buffered saline). 5: Unvaccinated, untreated control

Table 4. Effects of different routes of administration of *T. inchonensis* on villus height (μm), villus thickness (μm) and goblet cells number (in 1 mm length) in small intestine of broiler¹ on the 28 days old (the means \pm SEM)

Parameter	Part of intestine	Experimental groups				
		1	2	3	4	5
Villus height	Duodenum	6.66 \pm 0.092 ^b	6.58 \pm 0.086 ^{ab}	6.14 \pm 0.11 ^{ab}	5.98 \pm 0.19 ^a	6.00 \pm 0.070 ^a
	Jejunum	7.74 \pm 0.170 ^b	7.34 \pm 0.180 ^b	6.78 \pm 0.110 ^a	6.64 \pm 0.12 ^a	6.64 \pm 0.100 ^a
	Ileum	5.32 \pm 0.058 ^c	5.70 \pm 0.150 ^d	4.76 \pm 0.120 ^b	4.42 \pm 0.13 ^a	4.50 \pm 0.150 ^a
Villus thickness	Duodenum	2.08 \pm 0.050	2.24 \pm 0.102	1.84 \pm 0.070	1.84 \pm 0.06	1.78 \pm 0.070
	Jejunum	1.98 \pm 0.073	1.86 \pm 0.090	1.86 \pm 0.087	1.78 \pm 0.073	1.84 \pm 0.080
	Ileum	1.98 \pm 0.037 ^b	1.70 \pm 0.044 ^{ab}	1.66 \pm 0.050 ^a	1.64 \pm 0.05 ^a	1.62 \pm 0.058 ^a
Goblet cells number	Duodenum	94.8 \pm 2.28	90.4 \pm 3.76	86.4 \pm 2.31	90.4 \pm 2.24	87 \pm 1.64
	Jejunum	96.0 \pm 2.21 ^b	93.4 \pm 2.63 ^{ab}	91.6 \pm 2.63 ^a	89.2 \pm 3.35 ^a	91.8 \pm 1.15 ^a
	Ileum	248 \pm 23.0 ^b	155 \pm 16.6 ^a	147 \pm 7.65 ^a	152 \pm 8.10 ^a	147.2 \pm 6.15 ^a

^{a-d}Means within a row with no common superscripts differ significantly ($P \leq 0.05$).

1= Vaccinated group "treated with 10^6 *T. inchonensis* continuously dosed in feed from day 1 to day 13. 2: Vaccinated group "treated" with 10^6 *T. inchonensis* pulse-dosed in feed on days 1 to 5; 8 & 9 and 12 & 13. 3: Vaccinated group "treated" with 10^6 *T. inchonensis* by subcutaneous injection on days 1, 6 and 12. 4: Vaccinated group untreated, but injected with carrier (phosphate buffered saline). 5: Unvaccinated, untreated control

experiment, but these were not statistically considerable with other routes of administration. It is not uncommon that the use of bacteria, does not notably improve bird performance (16, 17) although growth improvement by probiotics has been reported (18, 19). These inconsistent data might be attributable to differences in properties of bacteria species to

be studied, inclusion dosage and timing, and feed composition and digestibility. The present findings demonstrate that the development of thymus, liver, and bursa of Fabricius was not influenced by different routes of administration of *T. inchonensis*, even though the difference in the spleen of birds aged 14 days was much more apparent ($P < 0.05$) in group 2,

Table 5. Effects of different routes of administration of *T. inchonensis* on villus height (μm), villus thickness (μm) and goblet cells number (in 1 mm length) in small intestine of broiler¹ on the 42 days old (the means \pm SEM)

Parameter	Part of intestine	Experimental groups				
		1	2	3	4	5
Villus height	Duodenum	7.78 \pm 0.130 ^b	7.16 \pm 0.230 ^{ab}	6.62 \pm 0.110 ^a	6.58 \pm 0.14 ^a	6.58 \pm 0.120 ^a
	Jejunum	10.22 \pm 0.290 ^c	8.12 \pm 0.058 ^b	7.14 \pm 0.092 ^a	7.26 \pm 0.074 ^a	7.12 \pm 0.130 ^a
	Ileum	6.46 \pm 0.160 ^b	6.10 \pm 0.109 ^b	5.08 \pm 0.096 ^a	5.14 \pm 0.067 ^a	5.06 \pm 0.067 ^a
Villus thickness	Duodenum	2.90 \pm 0.100 ^b	2.24 \pm 0.107 ^{ab}	1.94 \pm 0.060 ^a	1.94 \pm 0.05 ^a	1.98 \pm 0.900 ^a
	Jejunum	3.00 \pm 0.070 ^c	2.28 \pm 0.066 ^b	1.76 \pm 0.050 ^a	1.80 \pm 0.04 ^a	1.74 \pm 0.050 ^a
	Ileum	2.86 \pm 0.066 ^b	2.00 \pm 0.070 ^a	1.84 \pm 0.050 ^a	1.80 \pm 0.044 ^a	1.82 \pm 0.037 ^a
Goblet cells number	Duodenum	131 \pm 8.08 ^b	120 \pm 3.97 ^b	94.8 \pm 2.57 ^a	91.0 \pm 2.07 ^a	93.8 \pm 2.28 ^a
	Jejunum	132 \pm 3.35 ^b	125 \pm 2.67 ^b	94.6 \pm 3.28 ^a	95.2 \pm 3.30 ^a	94.8 \pm 2.05 ^a
	Ileum	329 \pm 33.9 ^b	221 \pm 17.69 ^b	173 \pm 8.59 ^a	170.6 \pm 7.04 ^a	169.2 \pm 9.15 ^a

^{a-d}Means within a row with same superscripts differ significantly ($P \leq 0.05$).

1= Vaccinated group "treated with 10^6 *T. inchonensis* continuously dosed in feed from day 1 to day 13. 2: Vaccinated group "treated" with 10^6 *T. inchonensis* pulse-dosed in feed on days 1 to 5; 8 & 9 and 12 & 13. 3: Vaccinated group "treated" with 10^6 *T. inchonensis* by subcutaneous injection on days 1, 6 and 12. 4: Vaccinated group untreated, but injected with carrier (phosphate buffered saline). 5: Unvaccinated, untreated control

the development of lymphoid organs was not influenced by other routes of administration.

The results of the current study showed that *T. inchonensis* improved the development of the histomorphologic structure of small intestine and caecal tonsil lymphoid tissues of broiler chickens, mainly when it was used orally. On the 14th and 28th days of sampling, the improvement was more effective on jejunum and ileum, respectively. However, at day 42, the last day of sampling, the tissue improvement in the jejunum was as good as in the ileum. Caspary (20) reported enhancement of the villus height proposes an expansion surface area capable of more excellent absorption of available nutrients. In this study, these two parameters (villus height and crypt depth) were increased significantly in the first group compared to other experimental groups, especially in the jejunum. Recently, some researchers reported a significant increase in the villus height and crypt depth due to the use of alphanune (prebiotic included 0.5 kg/ton alphanune, which is a yeast extract antibiotic alternative, mannan-oligosaccharide) and biomin (symbiotic included 1 kg/ton biomin, which is a combination of the probiotic strain *Enterococcus faecium*, immune-modulating substances derived from sea algae, and a prebiotic derived from chicory) in broiler chickens (15), which is in agreement with the findings of the current study. Besides, it was proposed that symbiotic and probiotic supplementations

increased villus height, crypt depth ratio significantly, and the villus height numerically increased (21). In this regard, it is demonstrated that greater villous height is an indicator that the function of intestinal villi is activated (22). By contrast, it is reported that shortening of the villi and deeper crypts may lead to poor nutrient absorption, increased secretion in the gastrointestinal tract, and lower performance (23). On the other hand, the results of the present study show significant increase in goblet cells number, especially in the ileum. Similarly, a significant increase in the number of goblet cells and in mucin secretion at the surface of the jejunum villi had been observed when feeding broilers a mixture of carvacrol, cinnamaldehyde, and capsicum oleoresin (24). Moreover, the broilers had longer intestinal villus to gather with more goblet cells in the ileum after being fed essential oils from oregano, anise and citrus peel (25). It has been suggested that feeding wheat-based diet (containing enzyme Endofeed W (EEW) or growth promoters (thyme essential oil (TEO) or probiotic Primalac® (PP)) affects jejunal and ileal histomorphology of broilers at 28 and 42 days of age (26). Taken to gather, it seems that the number of goblet cells per villus increases as the villi grows (27), and goblet cells secrete throughout the gastrointestinal tract that forms an adherent gel on the mucosal surface and may play an important role in epithelial cell repair (28).

Here, a more interesting finding was the increase in and improvement of density and area of aggregated lymphoid tissue and the relationship of lymphoid area of caecal tonsil to the entire caecal tonsil circumference, which caused the diameters and wall thickness of caecal tonsil, height and thickness of nodular unit to increase. Indeed, the first group presented more significant improvement on lymphatic tissue of caecal tonsil compared to the second and third groups. In line with this study, some researchers observed similar results by dietary treatment with alphamune (a prebiotic) and biomin (a synbiotic) (15). The positive effects of biomin on immune system effectiveness and newly presented prebiotics that can manage various properties of the immune system, including those of the gut-associated lymphoid tissues are demonstrated (15). On the basis of the results of the present study, it seems that *T. inchonensis* can have positive effects on immune system effectiveness such as biomin.

Humoral immunity was evaluated by antibody response to NDV, and AI. The highest AI titers were observed in sera of birds in the group 2, but in all of treated groups, antibody level was significantly higher than untreated group. It was observed that titer in sera of birds of the group 2 were significantly higher than that of group 4 whose birds received only vaccine and no other treatment. Higher specific antibody titers to NDV induced by *T. inchonensis*, related with increased protection from NDV infection. Similarly AI titers of groups 1, 2, and 3 are higher than that of group 5. These data are in agreement with that of Talebi et al. (3) who reported that high dose of symbiotic (containing *Lactobacillus* and *Bifidobacterium*) improves the HI antibody titers for NDV and ELISA antibody for IBV compared with that of control group, and also with Esvaran and Conway (29) who reported that oral administration of *Lactobacillus* strain significantly enhanced IgG response and Sadeghi et al. (30), who found that probiotics can increase the systemic antibody response to some antigens in chickens. It was believed that binding of structural components of bacteria to Toll-like receptors (TLRS), which commonly expressed on the surface of dendritic cells and macrophages in the lamina propria may result in their promotion and differentiation. Upon promotion, they increase the activation and differentiation of various subsets of other immune system cells, leading to the secretion of cytokines like IL4, IL10, and TGF- β that are essential for

antibody production and isotype switching (31).

In conclusion, *T. inchonensis* treatment showed that it significantly improved and increased the small intestines (more significantly in jejunum and ileum) histomorphological structure and caeca tonsil lymphatic tissues, especially when used orally. Furthermore, it can be used as growth promoter for improvement of histomorphological structure of small intestine and also for increasing and improvement of density and area of aggregated lymphoid tissue of broilers as peripheral immune system, especially at 42 days of age. We recommend that the optimal route of administration of *T. inchonensis* for immune stimulation is pulse dosed in feed of broiler chickens.

REFERENCES

1. Manyi-Loh C, Mamphwelis S, Meyer E, Okoh A. Antibiotic use in agriculture and its consequential resistance in environmental sources: potential public health implications. *Molecules* 2018; 23: 795.
2. Ghafoor A, Naseem S, Younes M, Nazir J. Immunomodulatory effects of multistrain probiotics (Protexin TM) on broiler chicken vaccinated against avian influenza virus (H9). *Int J Poult Sci* 2005; 4: 777-780.
3. Talebi A, Amani S, Pourmahmod M, Saghaei P, Rezaie R. Symbiotic enhances immune responses against infectious bronchitis, infectious bursal disease, Newcastle disease and avian influenza in broiler chickens. *Vet Res Forum* 2015; 6: 191-197.
4. Nofouzi K, Aghapour M, Hamidian GH, Katiraei F, Stanford J, Ripley P. Oral administration of heat killed *Tsukamurella inchonensis* enhances immune responses and intestinal function in mice. *Vet Med* 2016; 61: 681-688.
5. Tarres MC, Gayol M, Picena JC, Alet N, Bottasso O, McIntyre G, et al. Beneficial effects of immunotherapy with extracts derived from Actinomycetales on rats with spontaneous obesity and diabetes. *Immunotherapy* 2012; 4: 487-497.
6. Al-Zubeedy AZ. Immune response in day old broiler chicks vaccinated against Newcastle disease virus. *Iraqi J Vet Sci* 2009; 23: 143-146.
7. Li XT, Wang B, Li JL, Yang R, Li SC, Zhang M, et al. Effects of dangguibuxue tang, a Chinese herbal medicine, on growth performance and immune responses in broiler chicks. *Biol Res* 2013; 46: 183-188.
8. Hernandez F, Madrid J, Garcia V, Orengo J, Megias MD. Influence of two plant extracts on broilers performance, digestibility, and digestive organ size. *Poult Sci* 2004; 83: 169-174.

9. Nofouzi K, Hassanzadeh Teroujeni A, Khordadmehr M, Madadi MS, Ranjbar VR, McIntyre G. Effects of spraying different dietary killed *Tsukamurella inchoensis* levels on growth performance, small intestine morphology and immune responses in Newcastle disease vaccinated Japanese quails. *J Anim Sci Res* 2019; 29: 73-89.
10. Stanford J, Stanford C. Mycobacteria and their world. *Int J Mycobacteriol* 2012; 1:3-12.
11. Marcu A, Vacaru-Opris I, Dumitrescu G, Ciachina LP, Marcu A, Nicula M, et al. The influence of genetics on economic efficiency of broiler chickens growth. *Anim Sci Biotechnol* 2013; 46: 339-346.
12. El-Katcha MI, El-Kkoly ME, Soltan MA, El-Gayar AH. Effect of dietary omega-3 to omega-6 ratio on growth performance, immune response, carcass traits and meat fatty acids profile of broiler chickens. *Poult Sci J* 2014; 2: 71-94.
13. Sakamoto K, Hirose H, Onizuka A, Hayashi M, Futamura N, Kawamura Y, et al. Quantitative study of changes in intestinal morphology and mucus gel on total par-enteral nutrition in rats. *J Surg Res* 2000; 94: 99-106.
14. Aptekmann KP, Baraldi Arton SM, Stefanini MA, Orsi MA. Morphometric analysis of the intestine of domestic quails (*Coturnix coturnix japonica*) treated with different levels of dietary calcium. *Anat Histol Embryol* 2001;30: 277-280.
15. Luo J, Zheng A, Meng K, Chang W, Bai Y, Li k, et al. Proteome changes in the intestinal mucosa of broiler activated by probiotic *Enterococcus faecium*. *J Proteomics* 2013;91: 226-241.
16. Erfani Majd N, Mayahi M, Sadeghi Moghadam A. The effect of alphamune and biomin on histomorphological structure of small intestine and caecal tonsil lymphoid tissue in broiler chicken. *Iran J Vet Res* 2014; 15: 30-35.
17. Wy Y, Zhen W, Geng Y, Wang Z, Guo Y. Effects of dietary *Enterococcus faecium* NC11MB 11181 supplementation on growth performance and cellular and humoral immune responses in broiler chickens. *Poult Sci* 2019; 98: 150-163.
18. Olnood CG, Beski SSM, Iji PA, Chot M. Delivery routes for probiotics: effects on broiler performance, intestinal morphology and gut midroflora. *Anim Nutr* 2015; 1: 192-202.
19. Schneitz C. Competitive exclusion in poultry—30 years of research. *Food Control* 2005; 16: 657-667.
20. Caspary WF. Physiology and pathophysiology of intestinal absorption. *Am J Clin Nutr* 1992; 55(1 Suppl):299S-308S.
21. Awad WA, Böhm J, Razzazi-Fazeli E, Ghareeb K, Zentek J. Effect of addition of a probiotic microorganism to broiler diets contaminated with deoxynivalenol on performance and histological alterations of intestinal villi of broiler chickens. *Poult Sci* 2006; 85: 974-979.
22. Shamoto K, Yamauchi K. Recovery responses of chick intestinal villus morphology to different refeeding procedures. *Poult Sci* 2000; 79: 718-723.
23. Xu ZR, Hu CH, Xia MS, Zhan XA, Wang MQ. Effects of dietary fructooligosaccharide on digestive enzyme activities, intestinal microflora and morphology of male broilers. *Poult Sci* 2003; 82: 1030-1036.
24. Jamroz D, Wiertelcki T, Houszka M, Kamel C. Influence of diet type on the inclusion of plant origin active sub-stances on morphological and histochemical characteristics of the stomach and jejunum walls in chickens. *J Anim Physiol Anim Nutr (Berl)* 2006; 90: 255-268.
25. Ghazanfari S, Mohammadi Z, Adib Moradi M. Effects of coriander essential oil on the performance, blood characteristics, intestinal microbiota and histological of broilers. *Braz J Poult Sci* 2015; 17: 419-426.
26. Khaksar V, Golian A, Raji A. Effect of feed additives on intestinal histomorphology of broilers fed wheat-based diet. *Iran J Appl Anim Sci* 2013; 3: 725-731.
27. Alam DA, Danopoulos S, Schall K, Sala FG, Almo-hazey D, Femandez GE, et al. Fibroblast growth factor 10 alters the balance between goblet and Paneth cells in the adult mouse small intestine. *Am J Physiol Gastrointest Liver Physiol* 2015; 308: G678-690.
28. Aihara E, Engevik KA, Montrose MH. Trefoil factor peptides and gastrointestinal function. *Annu Rev Physiol* 2017; 79: 357-380.
29. Esvaran M, Conway PL. Factors that influence the immunological adjuvant effect of *Lactobacillus fermentum* PC1 on specific immune responses in mice to orally administered antigens. *Vaccines (Basel)* 2016; 4: 24.
30. Sadegh AA, Shawrang P, Shakorzadeh S. Immune response of *Salmonella* challenged broiler chickens fed diets containing gallipro, a *Bacillus subtilis* probiotic. *Probiotics Antimicrob Proteins* 2015; 7: 24-30.
31. Vazquez MI, Catalan-Dibene J, Zlotnik A. B cells responses and cytokine production are regulated by their immune microenvironment. *Cytokine* 2015; 74: 318-326.